CYBERSEMINARS HSR&D: *Diffusion Tensor Imaging in Mild Traumatic Brain Injury*

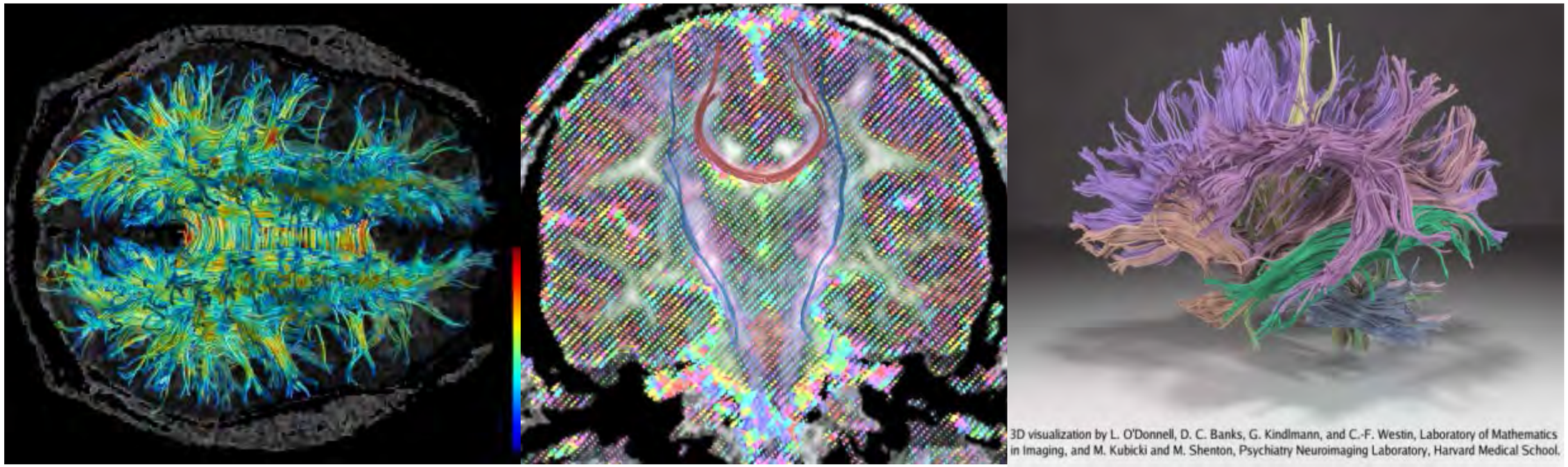

Martha E. Shenton, Inga Koerte, Ofer Pasternak, Sylvain Bouix, Alex Lin,
Yogesh Rathi, Marek Kubicki, Elisabeth Wilde, David Tate, Michael Weisend, Robert Stern, Ross Zafonte

Psychiatry Neuroimaging Laboratory, BWH
Harvard Medical School
VA Boston Healthcare System

Poll Question #1

What is your primary role in the VA?

- Student, trainee, or fellow
- Clinician
- Researcher
- Manager or policy-maker
- Other

Poll Question #2

Which best describes your research experience?

- Have not done research
- Have collaborated on research
- Have conducted research myself
- Have applied for research funding
- Have led a funded research grant

Overview

- **Mild TBI: Millions Affected; Only More Recently is There Radiological Evidence**
- **Methodologies**
- **Fundamentals of Diffusion Tensor Imaging**
- **Beyond DTI**
  - Resolving Crossing Fibers
  - Multi-Shell Diffusion Imaging
  - Free Water Imaging
  - Harmonizing MR DTI Across Multiple Scanners/Sites
- **Diffusion Tensor Imaging and TBI**
  - Chronic Mild Traumatic Brain Injury (TBI)
  - Sports Concussions and Chronic Traumatic Encephalopathy (CTE)
- **MR Spectroscopy: The Virtual Biopsy & Multimodal Imaging in an ER & VA Sample**
- **PET Imaging: PK11195 in Complicated mTBI & Tau Imaging in Presumed CTE**
- **Animal Studies**

  - **Acknowledgements**
  - **Publications from our lab**
  - **Other References of Interest**

- **Mild Traumatic Brain Injury**

What we Know – Difficult to Diagnose

Lack of Appropriate Neuroimaging Tools

Mild Traumatic Brain Injury (Concussion)

- Each year, an estimated **1.7 million** people sustain a TBI (concussion) in the United States.
- Mild Traumatic Brain Injury (mTBI) is a **very common sports** injury.
- 15-30% of mTBI patients experience **persistent post-concussive** symptoms (PPCS).
- **Decades later** (or even sooner) mTBI may lead to **neurodegenerative disease**.
- **Military Relevance:**
  - Since Operation Iraqi Freedom (OIF) and Operation Enduring Freedom (OEF), the United States Armed Forces has documented **more than 300,000 cases of traumatic brain injury** (TBI)
  - 80-95% are classified as mTBI.
  - mTBI and PTSD **share similar symptoms**, and both can be present in the same individual.

Mild Traumatic Brain Injury

- mTBI is **difficult to diagnose** and characterize:
  - CT and conventional MRI are not optimal for detecting subtle injuries.
  - Disorder is very heterogeneous, difficult to study with standard population techniques.
- **Advanced neuroimaging** is useful for **diagnosis and prognosis**.
  - **Diffusion imaging** has shown good sensitivity to detect brain alterations in living individuals with mTBI.
  - **Subject-Specific** analyses are best suited to study brain injuries.

• Methodologies

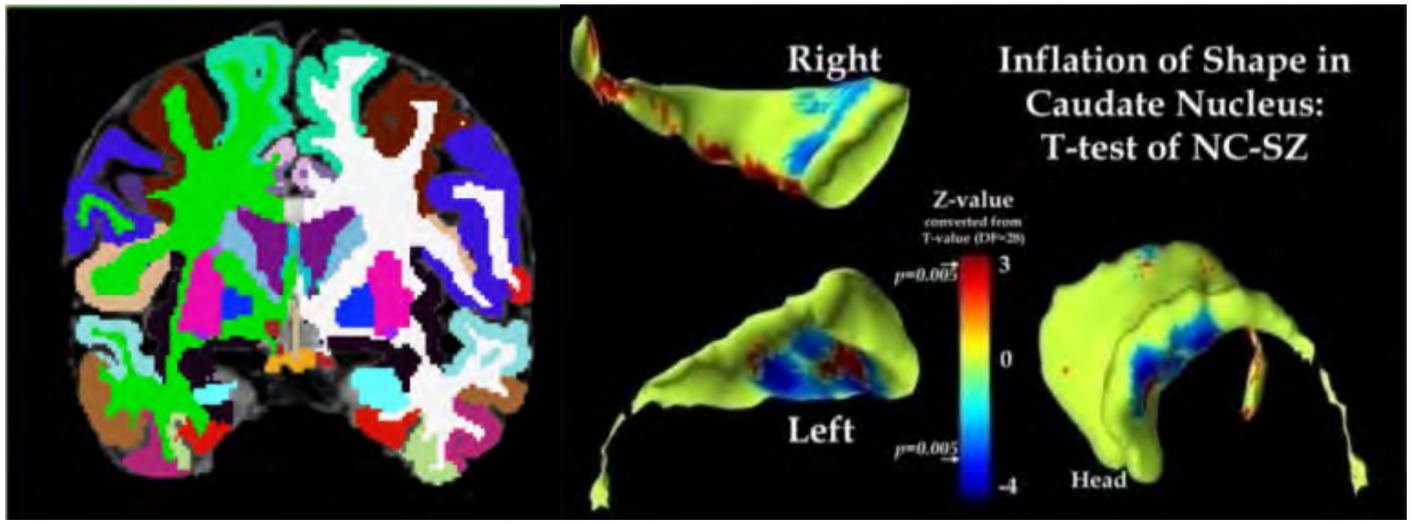

Morphometry

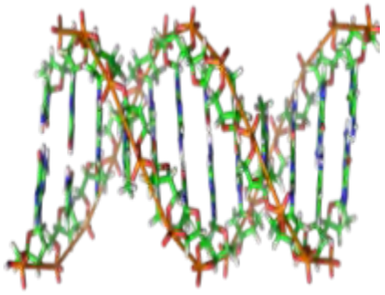

Genetics

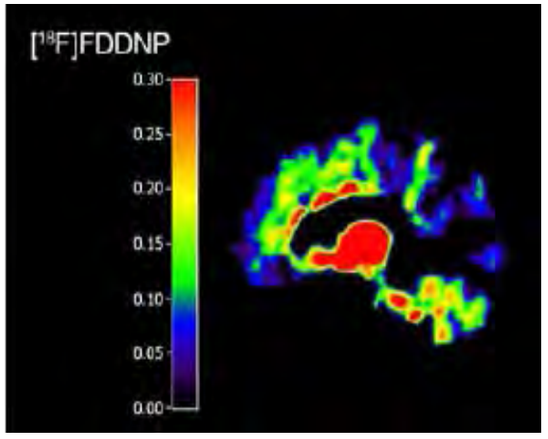

PET

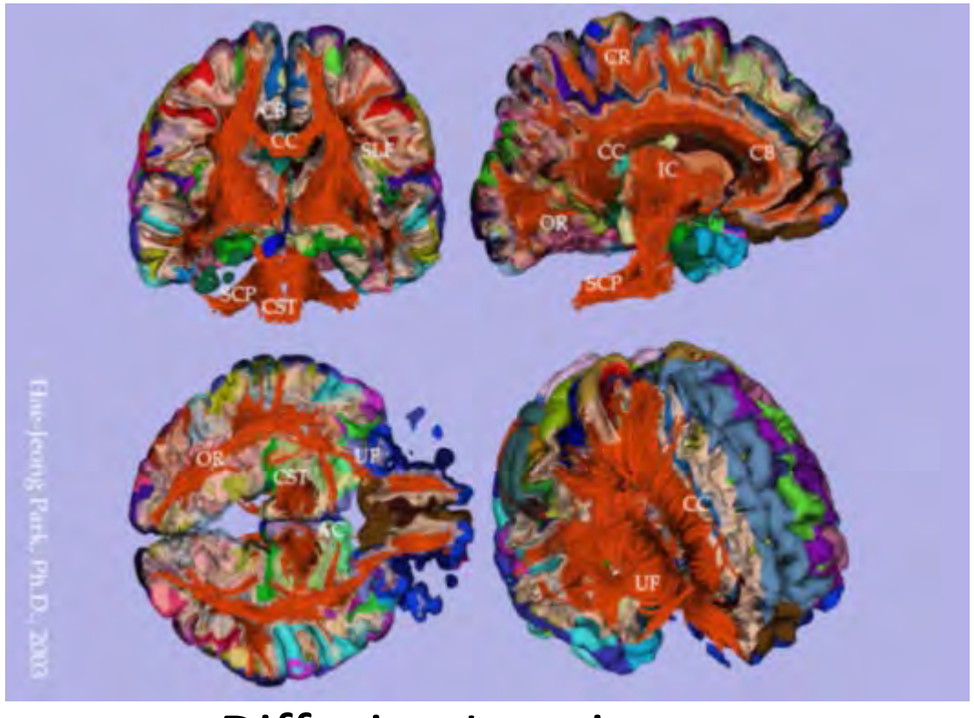

Diffusion Imaging

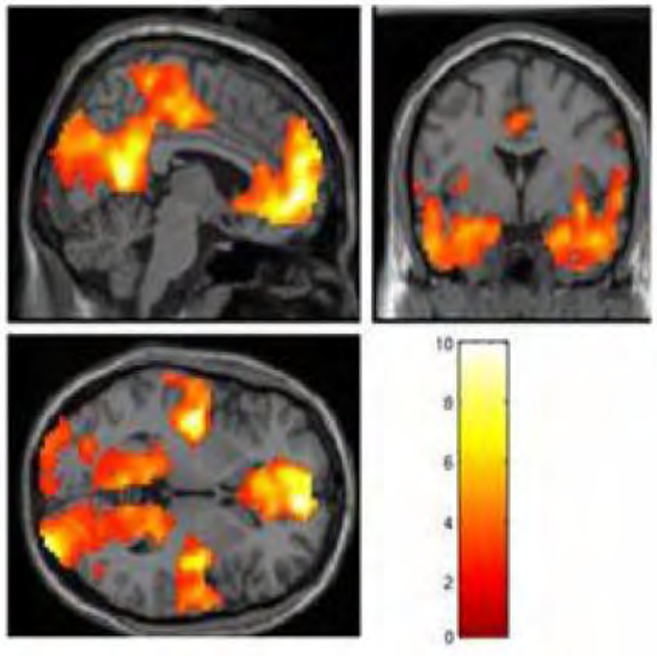

Functional Imaging

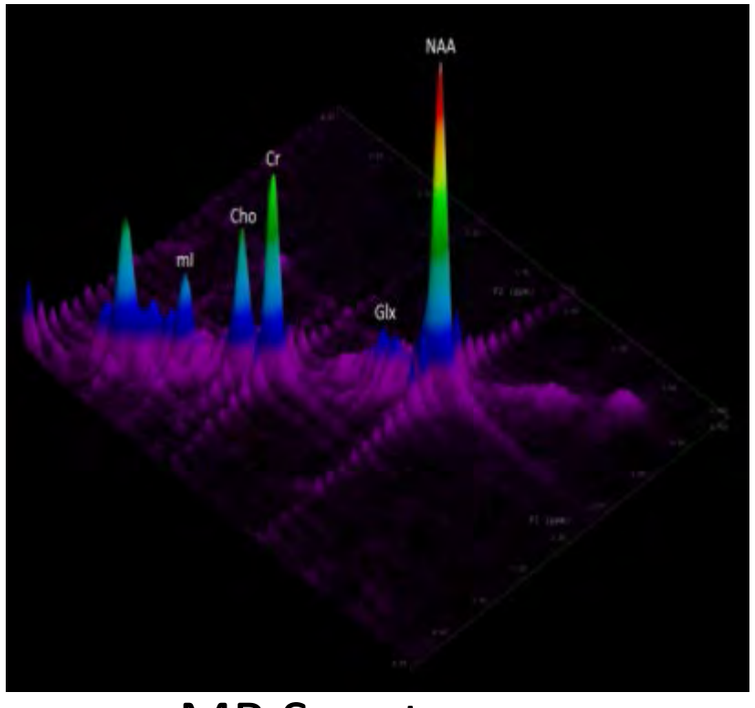

MR Spectroscopy

• Diffusion Tensor Imaging

Fundamentals

How the Brain Works

Diffusion Tensor Imaging

- 1827 - Robert Brown observes movement of plant spores floating in water.
- 1905 - Albert Einstein gives the first satisfactory theoretical treatment of Brownian motion.
- 1965 - Stejskal and Tanner develop the experimental method to detect water diffusion in living tissue.
- 1986 - Le Bihan introduces Diffusion MR Imaging.
- 1995 - Basser develops a method to obtain DTI and to quantify diffusion.
- 1996 - Pierpaoli - first DTI application to human brain.
- 1998 - Buchsbaum - first DTI study of schizophrenia.
- 2002 - Arfanakis - first DTI study of TBI.

Water Diffusion in the Brain has *Directionality*

Isotropic diffusion

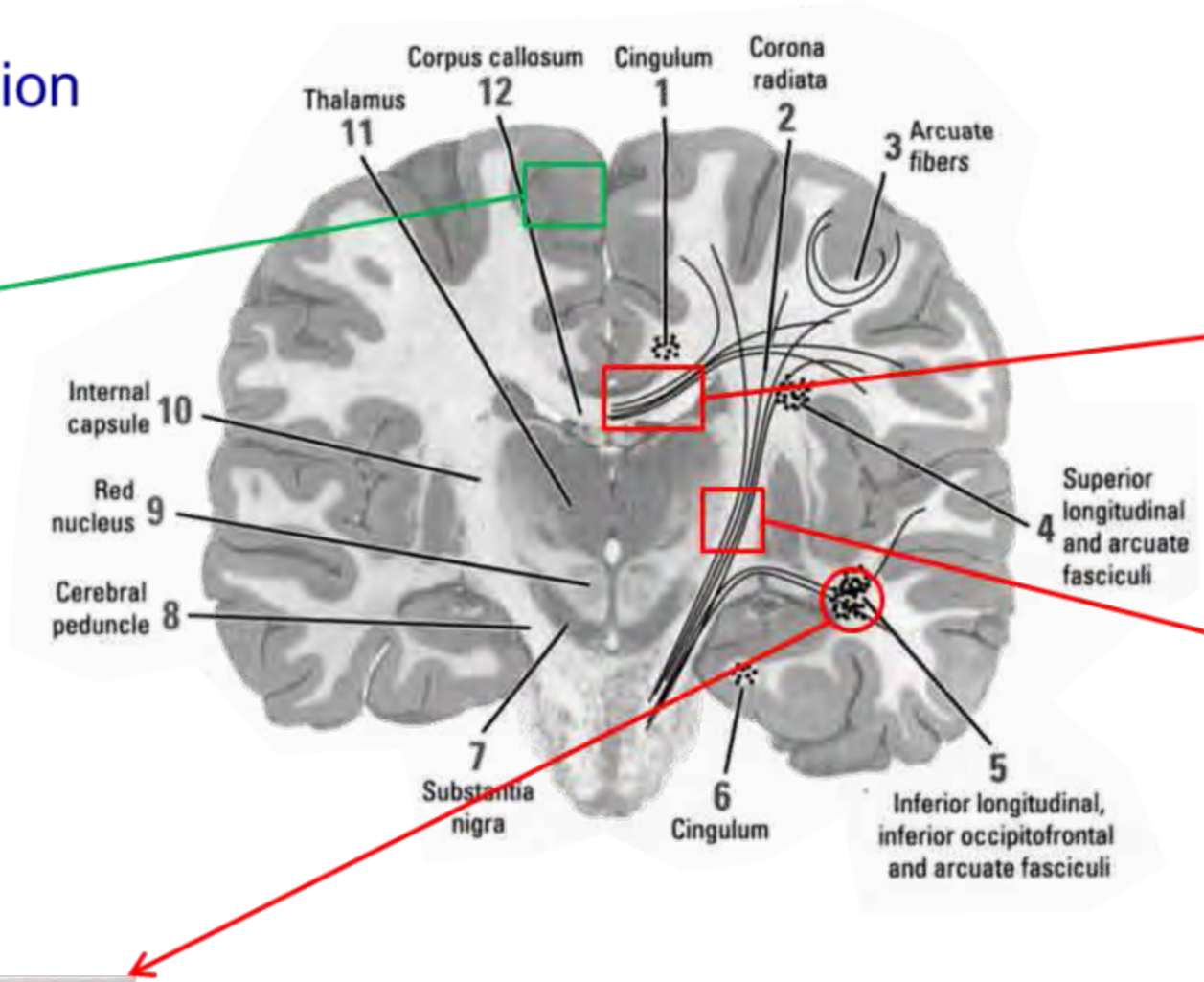

Anisotropic diffusion

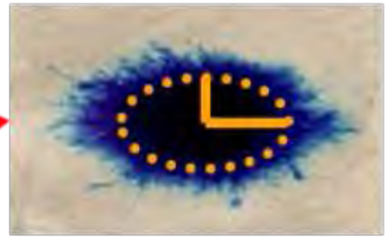



Possible sources of anisotropy:

- Axonal membranes of *densely packed axons hinder diffusion perpendicularly* to the fiber long axis.
- Myelin may also modulate anisotropy.

(Bouix S)

Diffusion Tensor Imaging

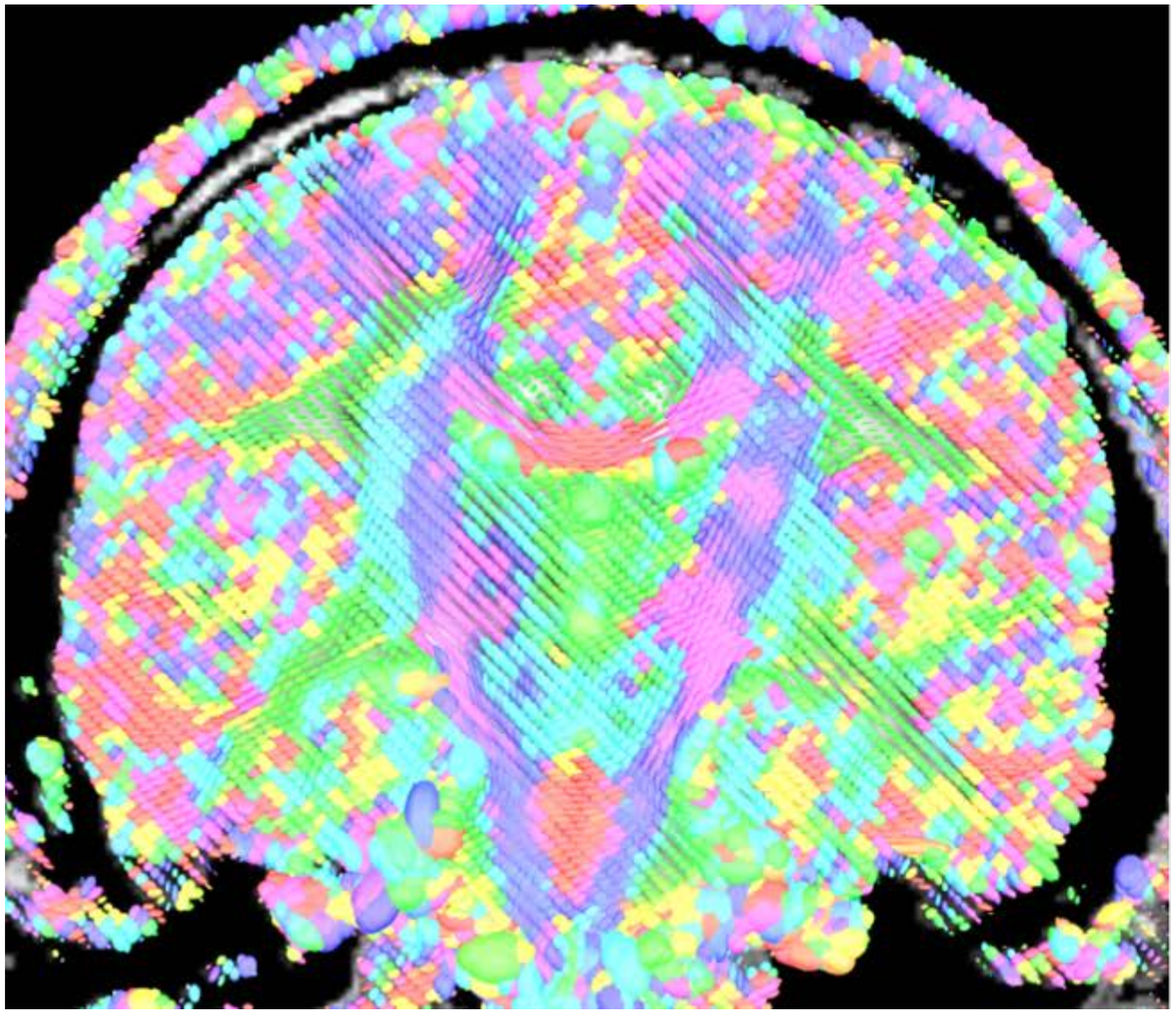



- At each location, the diffusion behavior of water is modeled as an ellipsoid.
- In medical imaging this ellipsoid is called a diffusion tensor.

DTI Derived Measures

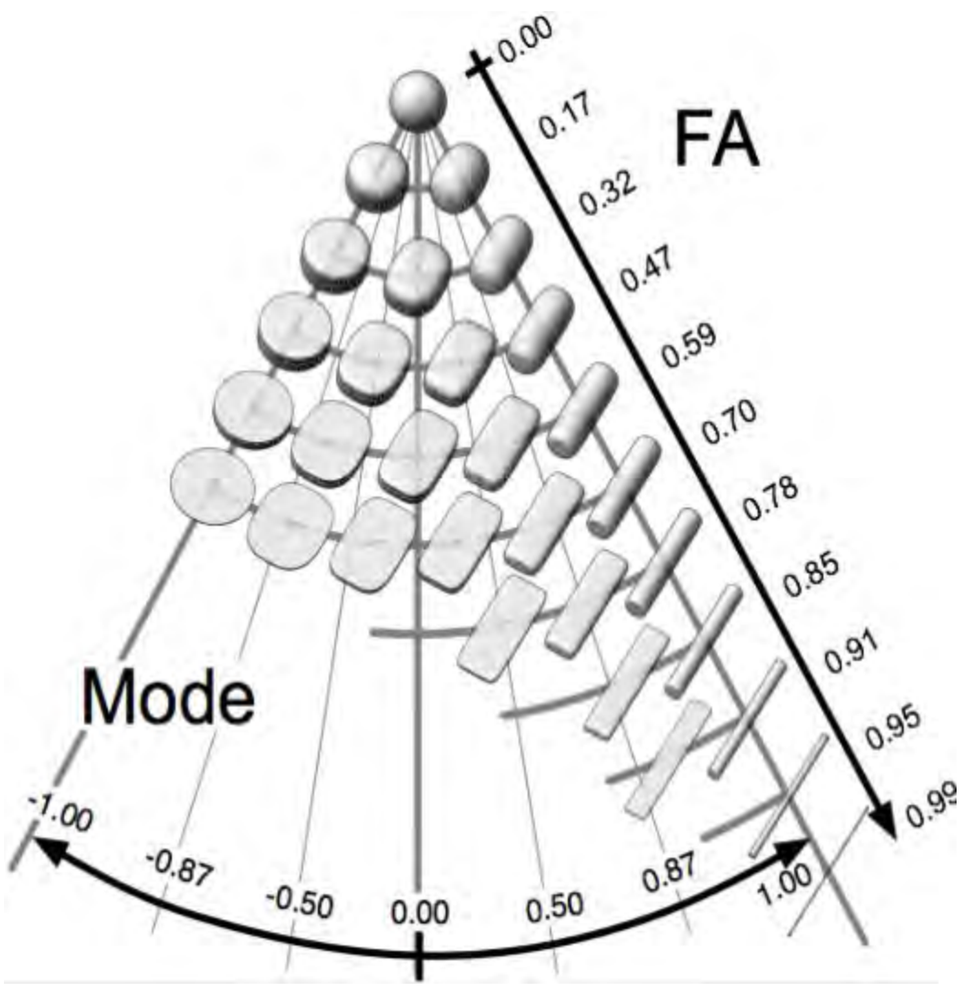

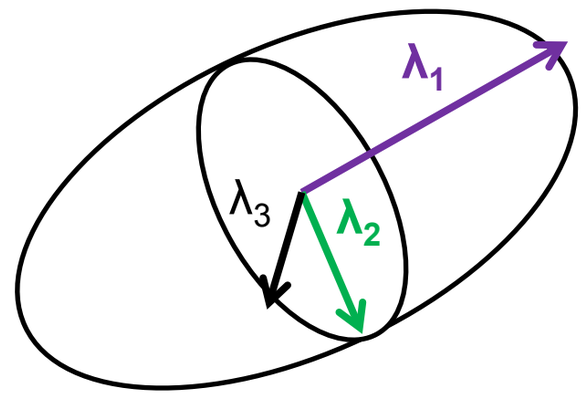

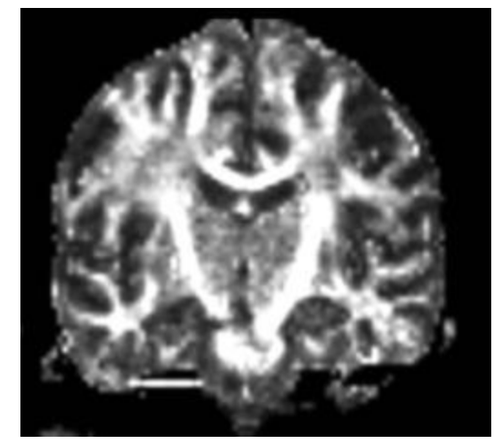

Fractional Anisotropy:

$$\sqrt{\frac{1}{2}}\frac{\sqrt{(\lambda_1-\lambda_2)^2+(\lambda_2-\lambda_3)^2+(\lambda_3-\lambda_1)^2}}{\sqrt{\lambda_1^2+\lambda_2^2+\lambda_3^2}}$$

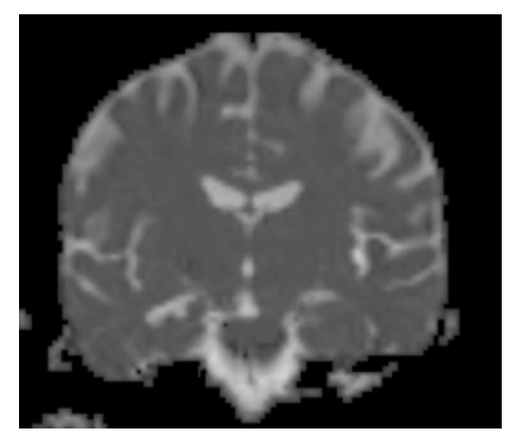

Mean Diffusivity: $(\lambda_1+\lambda_2+\lambda_3)/3$
Axial Diffusivity: λ_1
Radial Diffusivity: $(\lambda_2+\lambda_3)/2$

From Tensors to Tracts

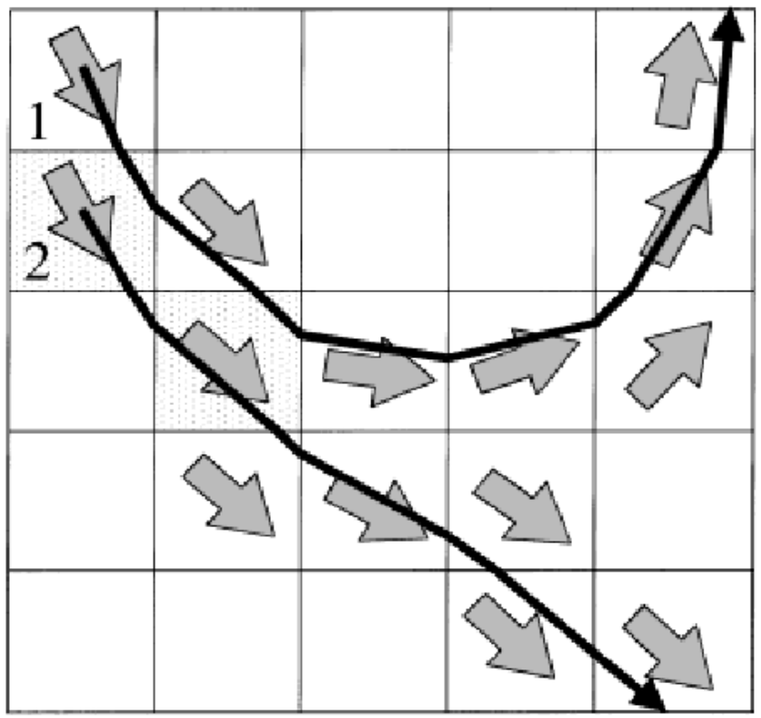

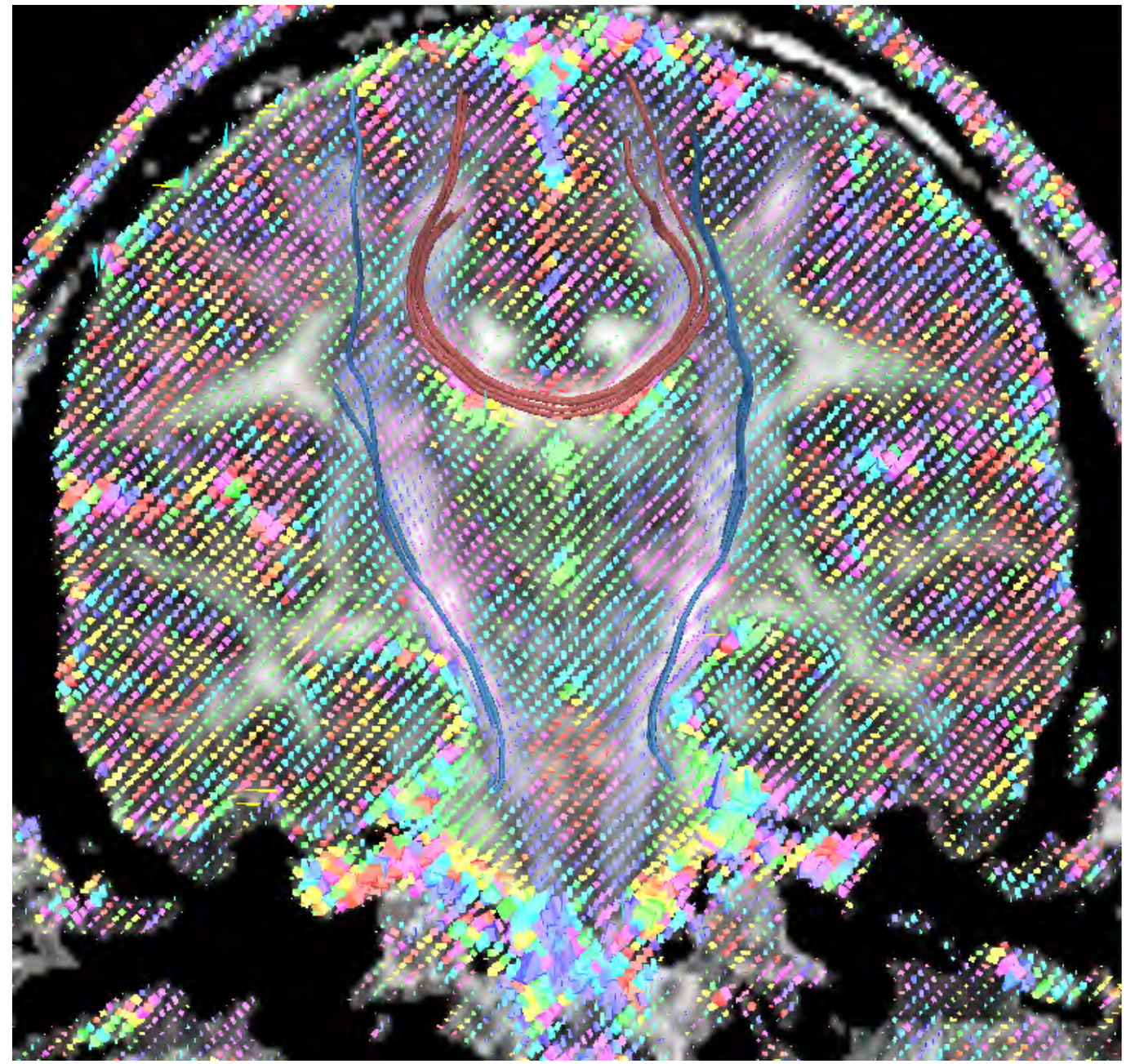

- Associate the major diffusion direction with the tangent to a curve.
- Estimate the curve from its tangents.

Full Brain Tractography

- Streamlines are not axons, only ***macroscopic structure*** of white matter bundles.
- Voxel size: mm
- Axon diameter: micrometers.

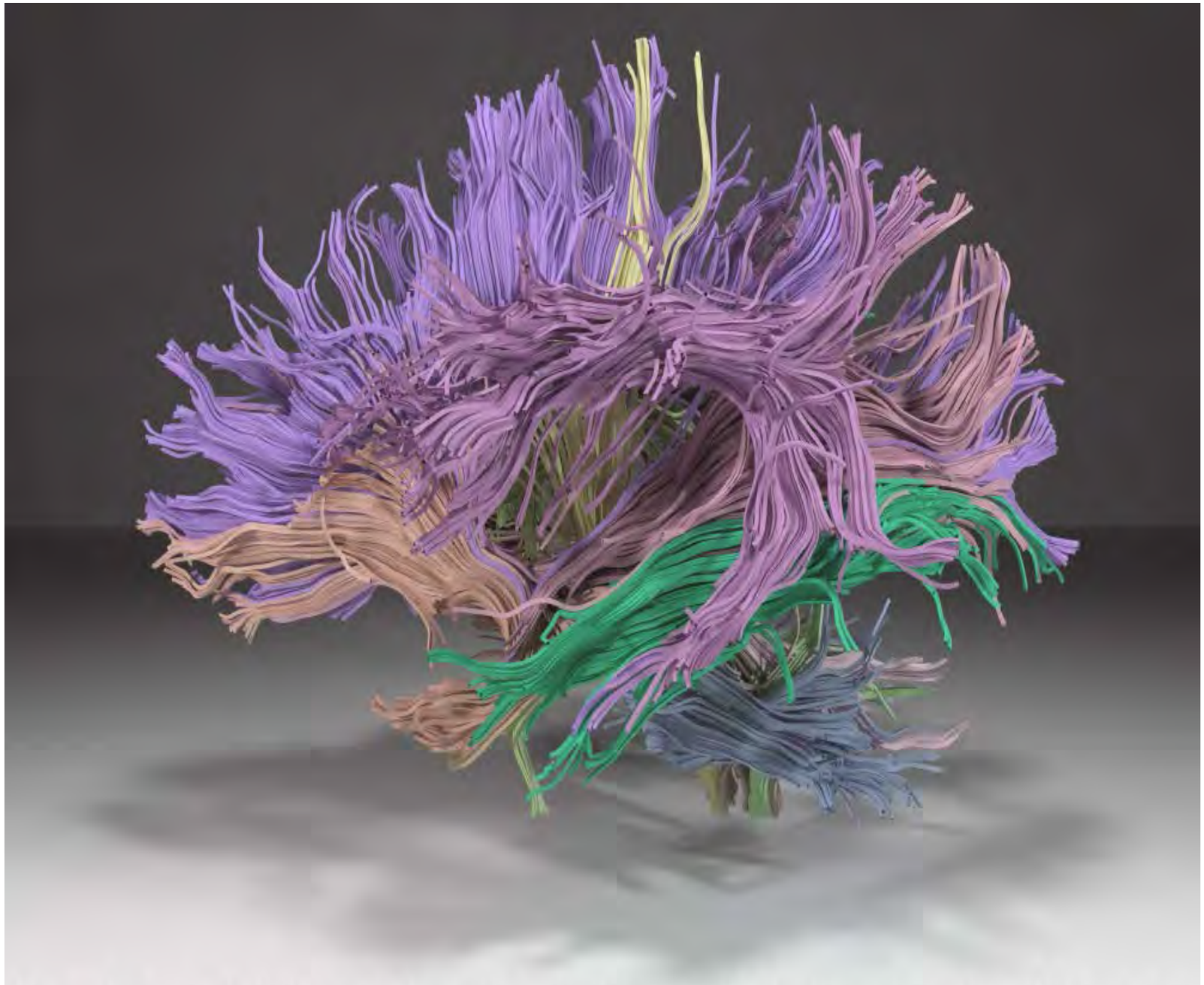

3D visualization by L. O'Donnell, D. C. Banks, G. Kindlmann, and C.-F. Westin, Laboratory of Mathematics in Imaging, and M. Kubicki and M. Shenton, Psychiatry Neuroimaging Laboratory, Harvard Medical School.

- **Beyond Diffusion Tensor Imaging**

Resolving Crossing Fibers

Multi-Tensor Tractography



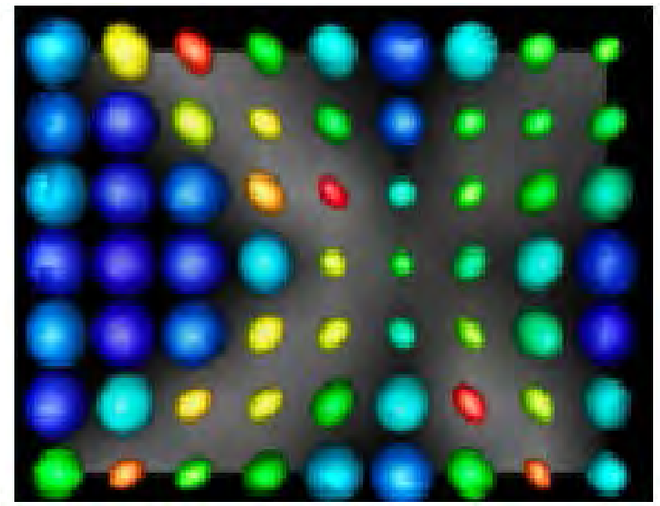

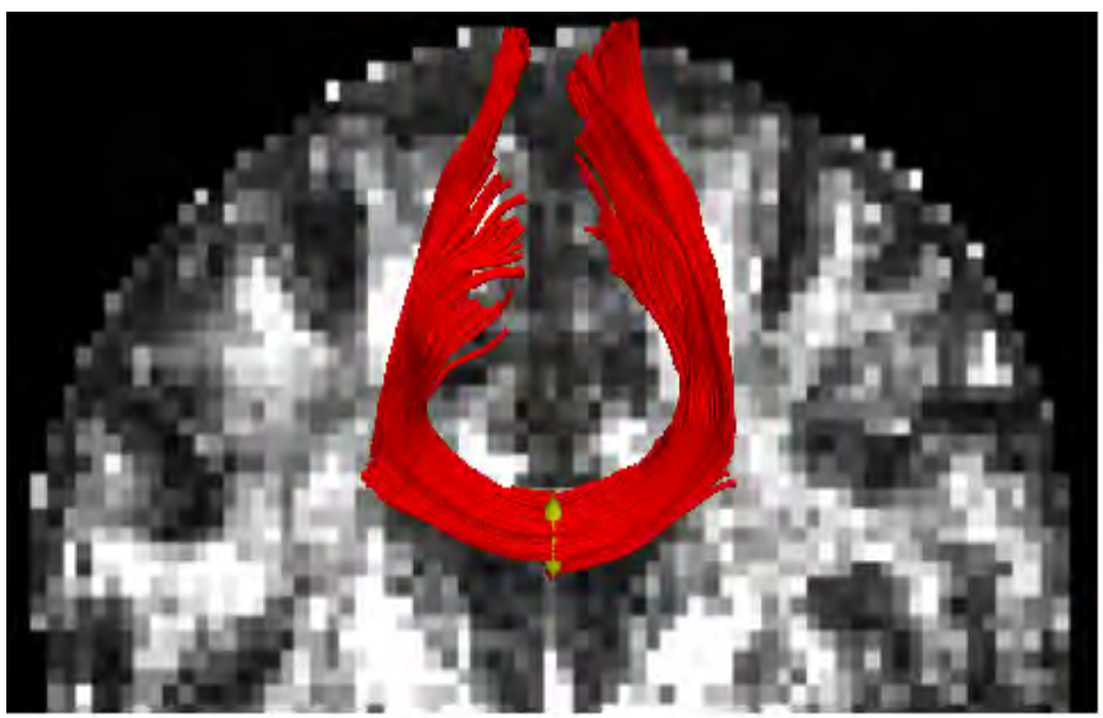

single-tensor

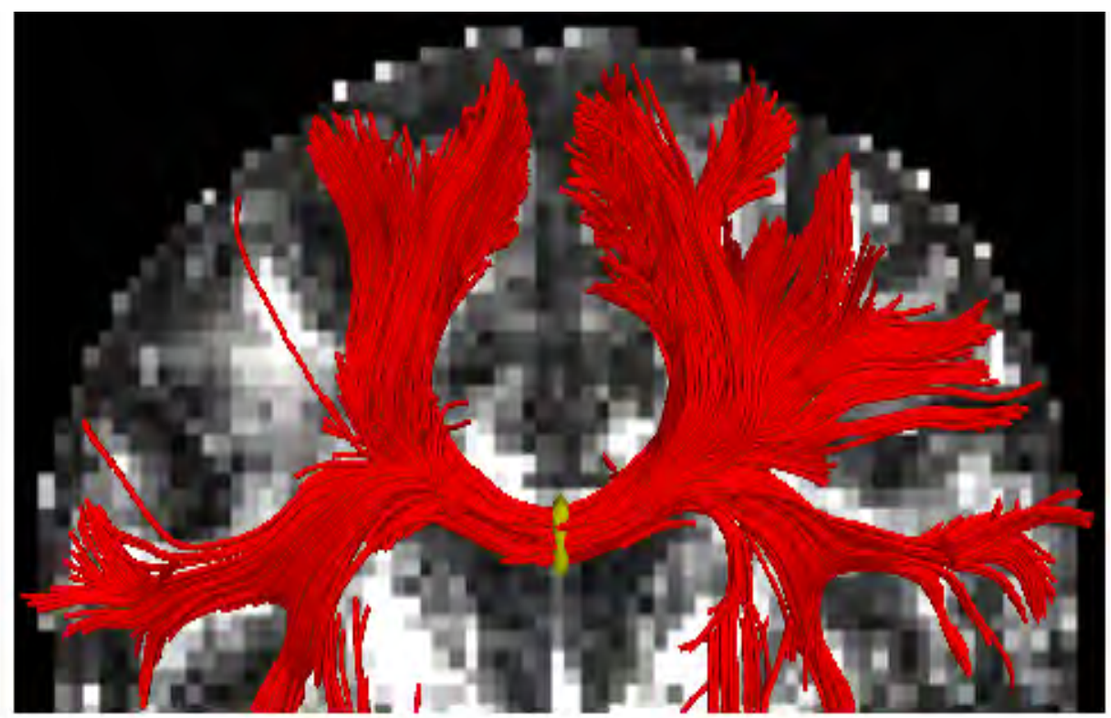

filtered two-tensor

(Malcolm, Shenton & Rathi, IEEE TMI 2010)

- **Beyond Diffusion Tensor Imaging**

Multi-Shell Diffusion Imaging

Multi-Shell Diffusion Imaging

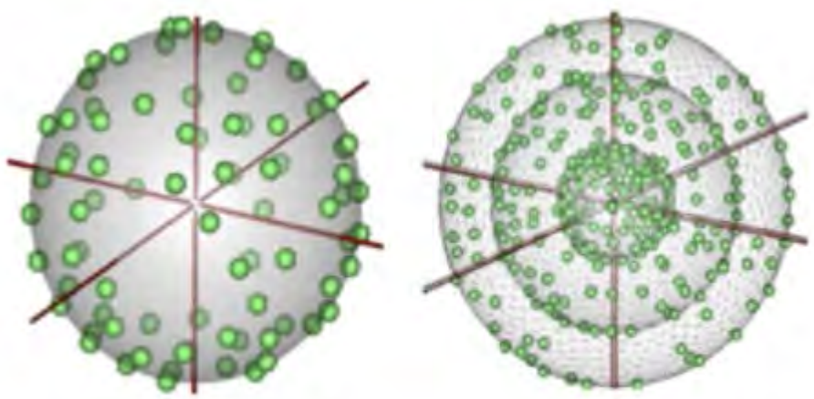

single-shell dMRI (DTI, HARDI)

multi-shell dMRI (3D diffusion function)

- Diffusion acquisition with multiple directions and multiple b-values extending to **high b-values**.
- Allows access to parameters with better tissue specificity than FA.

Kurtosis	Sensitive to Myelin
Zero Probability	Measure of restriction
Displacement	Axon sizes (diameter)

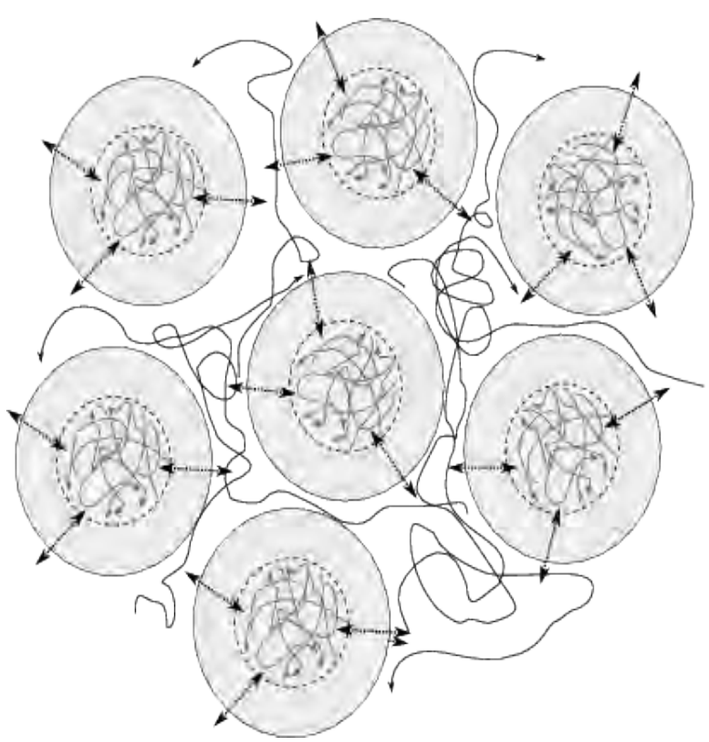

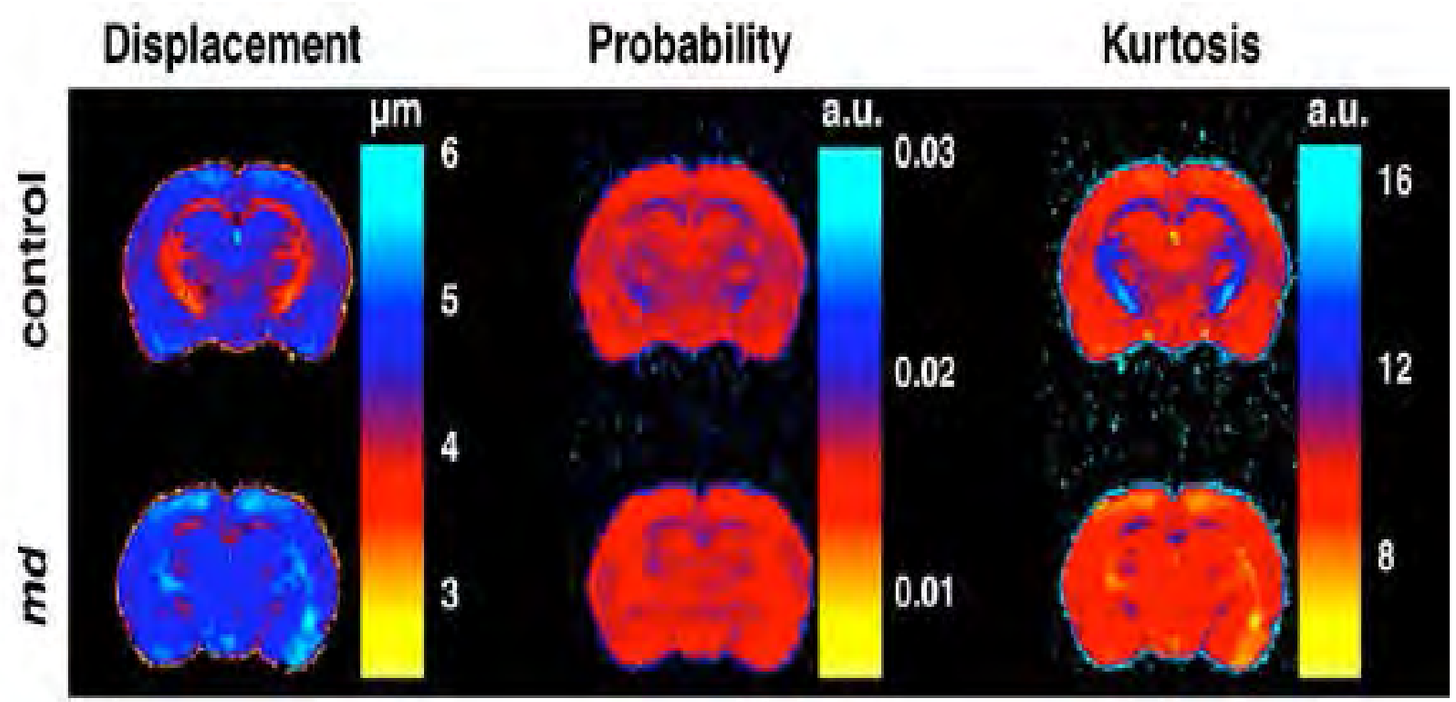

Rapid Multi-Shell Diffusion Imaging

- Traditional multi-shell acquisition requires upwards of 45-60 minutes.
- We have developed algorithms to recover the diffusion signal from fewer measurements – 16-20 samples/shell.
- Combining hardware acceleration, the scan time reduces significantly (reduction by a factor of 9).
- Existing data sets acquired for analysis with single tensor model can be re-used for analysis using advanced multi-tensor models.

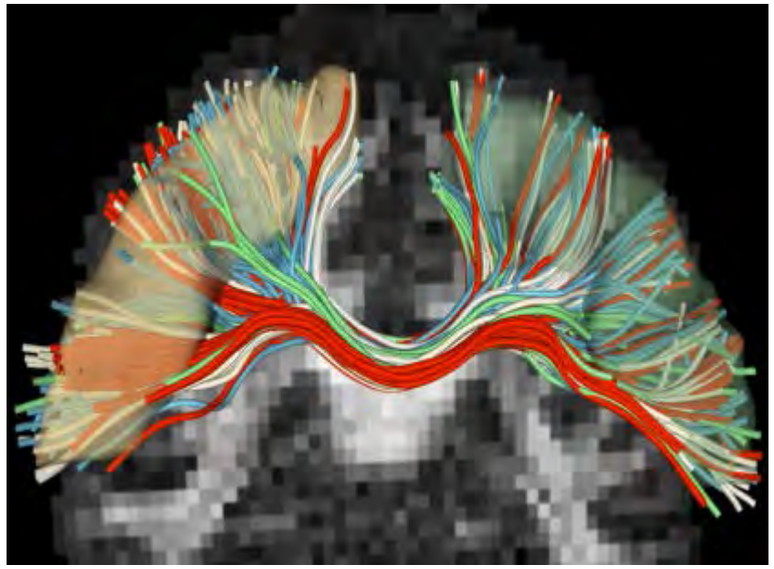

Overlap of tracts traced with different number of samples

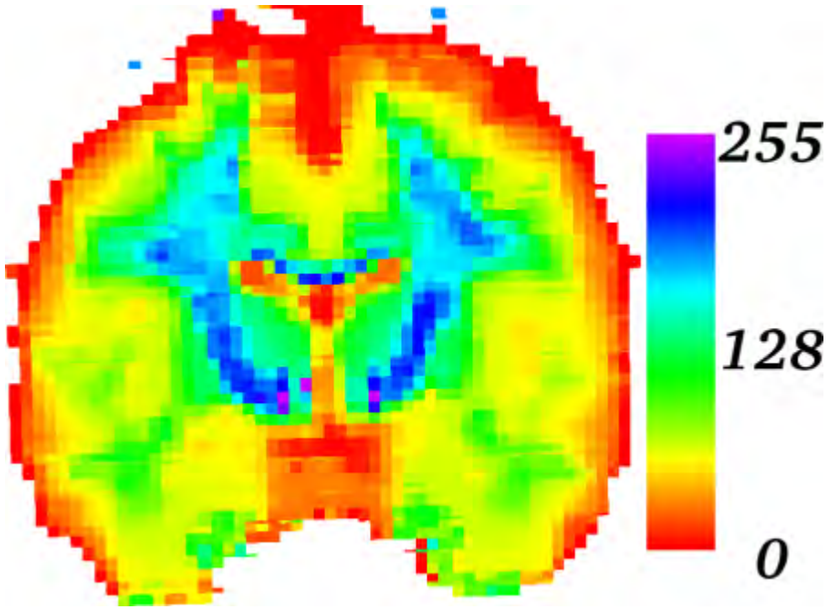

Restricted diffusion

(Rathi et al., 2011)

- **Beyond Diffusion Tensor Imaging**

Free-Water Imaging

Free-Water Imaging

- Increased measurement specificity
- Signal from extracellular free-water
- Signal from water next to tissue
- Requires regular DTI acquisition

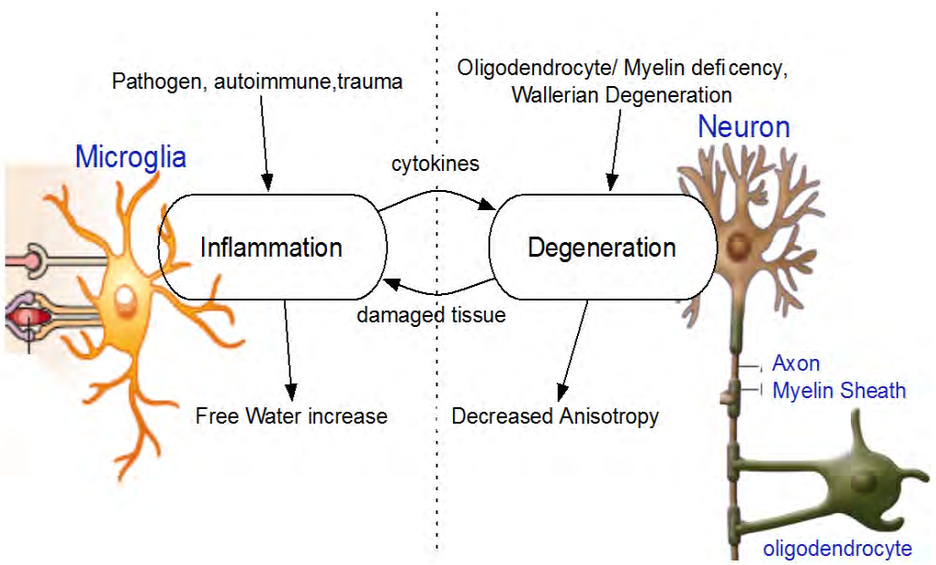

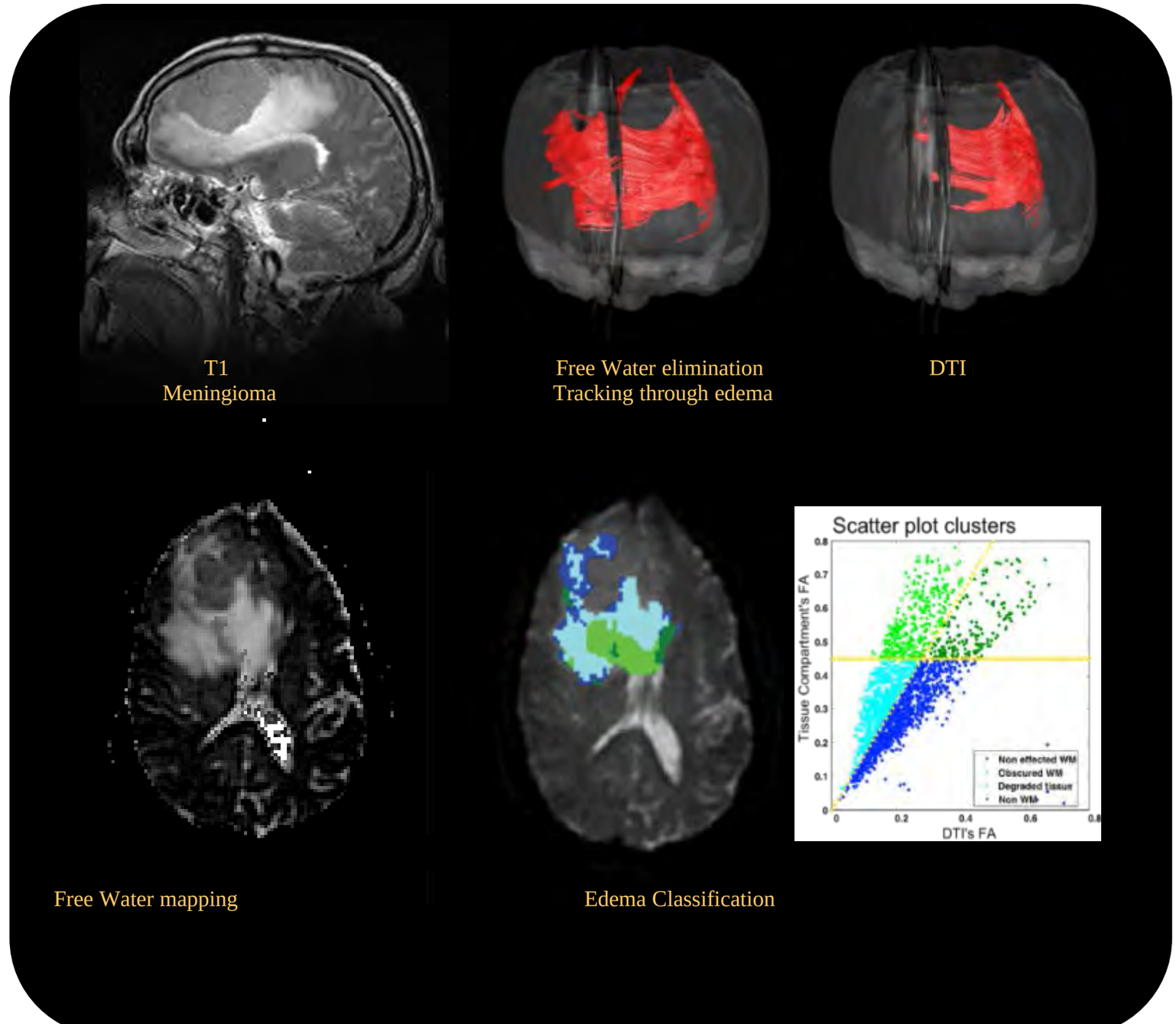

(Pasternak et al., MRM 2009; MICCAI 2012; J. Neuroscience 2012)

Neuroinflammation in First Episode Schizophrenia

- Disrupted connectivity in white matter (WM) neural circuits may explain many of the symptoms of schizophrenia, including delusions, disordered thought and speech, emotional and behavioral deficits, and hallucinations.

- **Myelin alteration:**
  Reduced oligodendrocyte counts.
  Decreased amount of macromolecules in WM.
  Abnormal expression of genes involved in myelin production.

- **Neuroinflammation:**
  Increased cytokines, Reduced risk of psychosis following treatment with Glucocortico-steroids
  Increased binding potential of a microglia (PET).

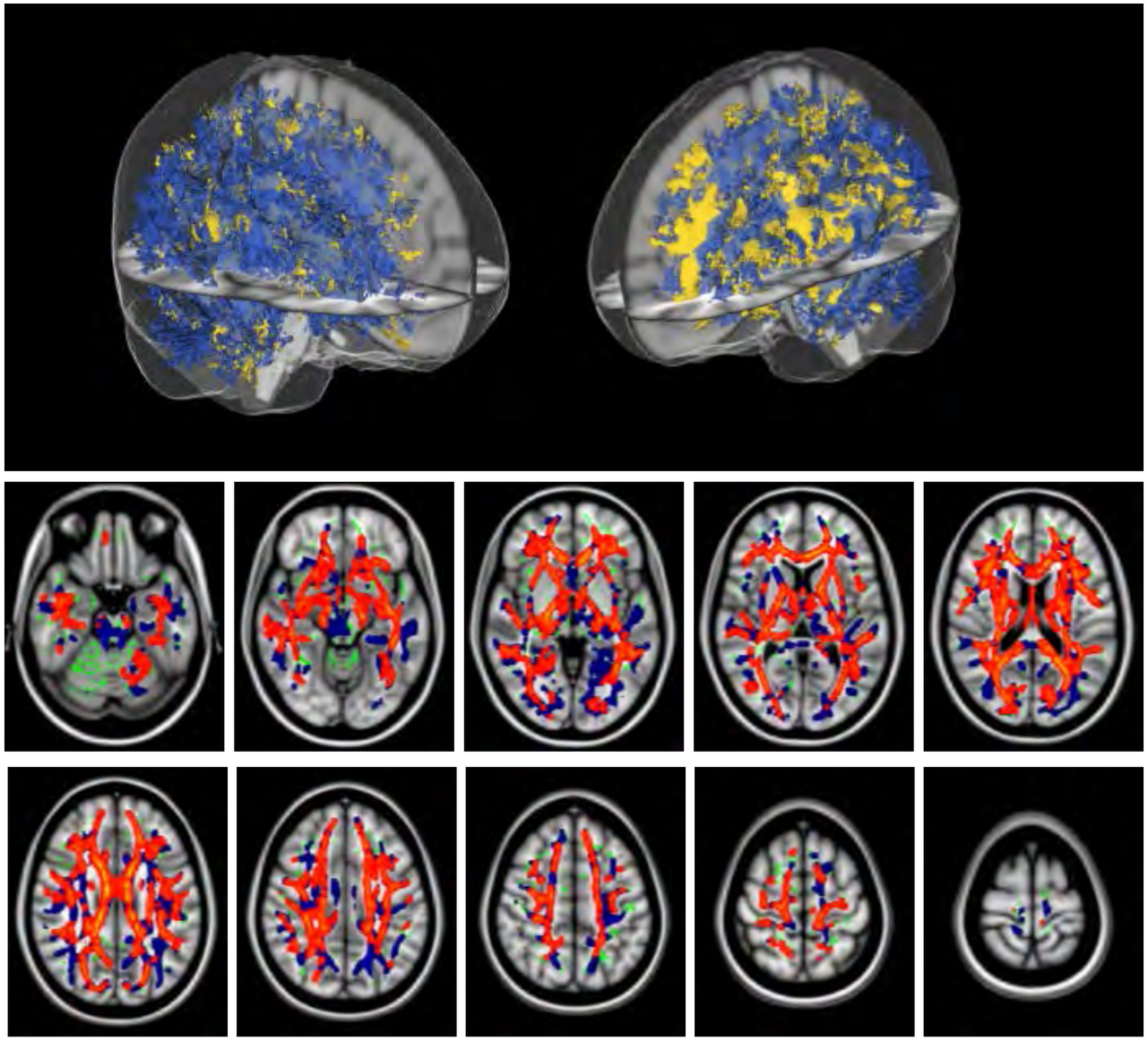

DTI finds widespread decreased FA (red) and increased MD (blue) – Do these findings suggest widespread myelin deficiencies in first episode schizophrenia?

(Pasternak et al., J. Neuroscience 2012)

Neuroinflammation in First Episode Schizophrenia

- All FA_T findings are in the frontal lobe.
- Coincides with the frontal findings in the literature.
- Fibers in the frontal lobe are myelinated late, thus could be more vulnerable to inflammation.
- Chronic Inflammation might cause degeneration in a neurodegenerative pattern.

Early detection and treatment with inflammation suppressing drugs could potentially reduce, or prevent the symptoms.

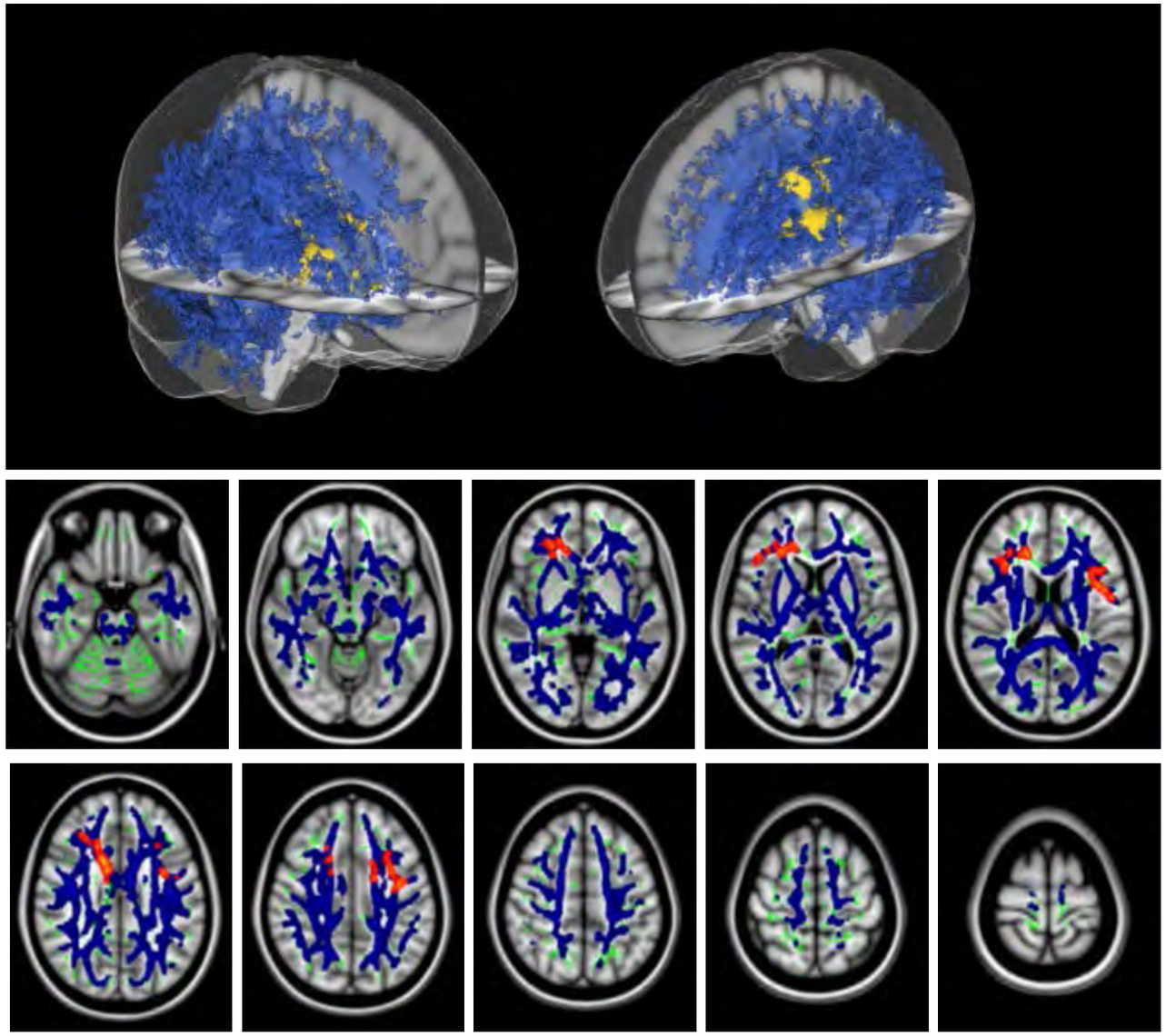

Free-water imaging reveals that excessive extracellular volume (blue) explains most group differences, suggesting widespread neuroinflammation and localized axonal degeneration.

(Pasternak et al., J. Neuroscience 2012)

- **Beyond Diffusion Tensor Imaging**

Harmonization Across Sites

Harmonizing Diffusion MRI Data Across Multiple Scanners

Part of INTRuST

PI: Yogesh Rathi

Funded Secondary Study for Year 7: Begins October 2014

- **Goal:** Develop advanced mathematical algorithms to reduce the inter-scanner variability so that sophisticated data analysis can be done on the entire data set.
  - Objective #1: Use advanced ***machine learning techniques to learn regional variations*** in specific diffusion measures of interest from the set of healthy controls scanned at each site.
  - Objective#2: Keeping a specific site as the baseline, we will learn a nonlinear function that can ***map the diffusion measures of all healthy controls from all sites to the baseline site***.
  - Objective #3: This mapping will then be applied to all the patient data, leading to ***a data set that will include all sites and be usable by any study*** involving dMRI data.

- **Diffusion Tensor Imaging and Mild Traumatic Brain Injury**

Chronic mTBI

Mild Traumatic Brain Injury

- mTBI is **difficult to diagnose** and characterize:
  - CT and conventional MRI are not optimal for detecting subtle injuries.
  - Disorder is very heterogeneous, difficult to study with standard population techniques.
- **Advanced neuroimaging** is useful for **diagnosis and prognosis**.
  - **Diffusion imaging** has shown good sensitivity to detect brain alterations in living individuals with mTBI.
  - **Subject-Specific** analyses are best suited to study brain injuries.

Subject-Specific Abnormality Map

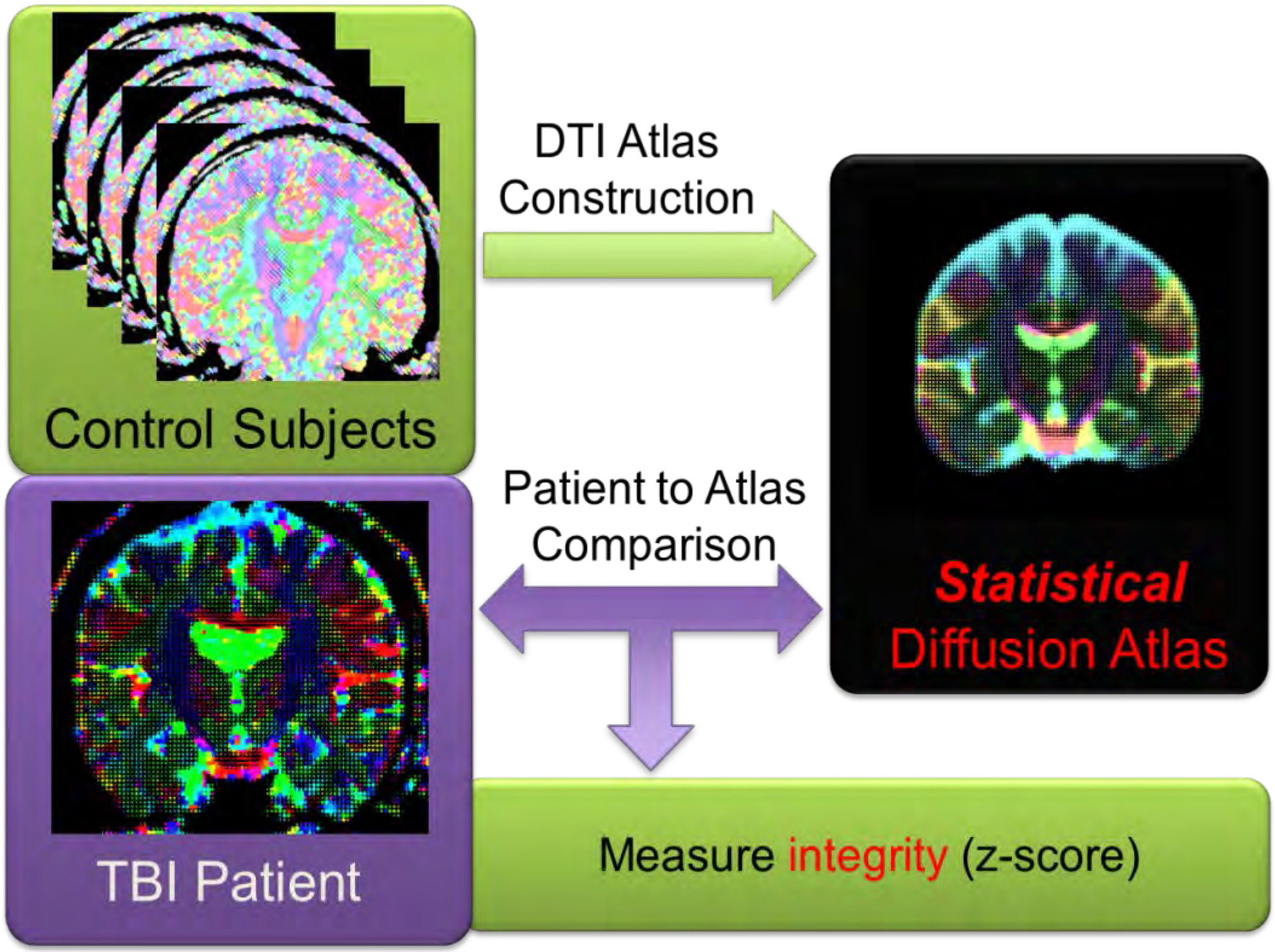

CIMIT®
Center for Integration of Medicine & Innovative Technology

(Bouix, Pasternak et al., Plos One, 2013)

Subject-Specific Abnormality Map

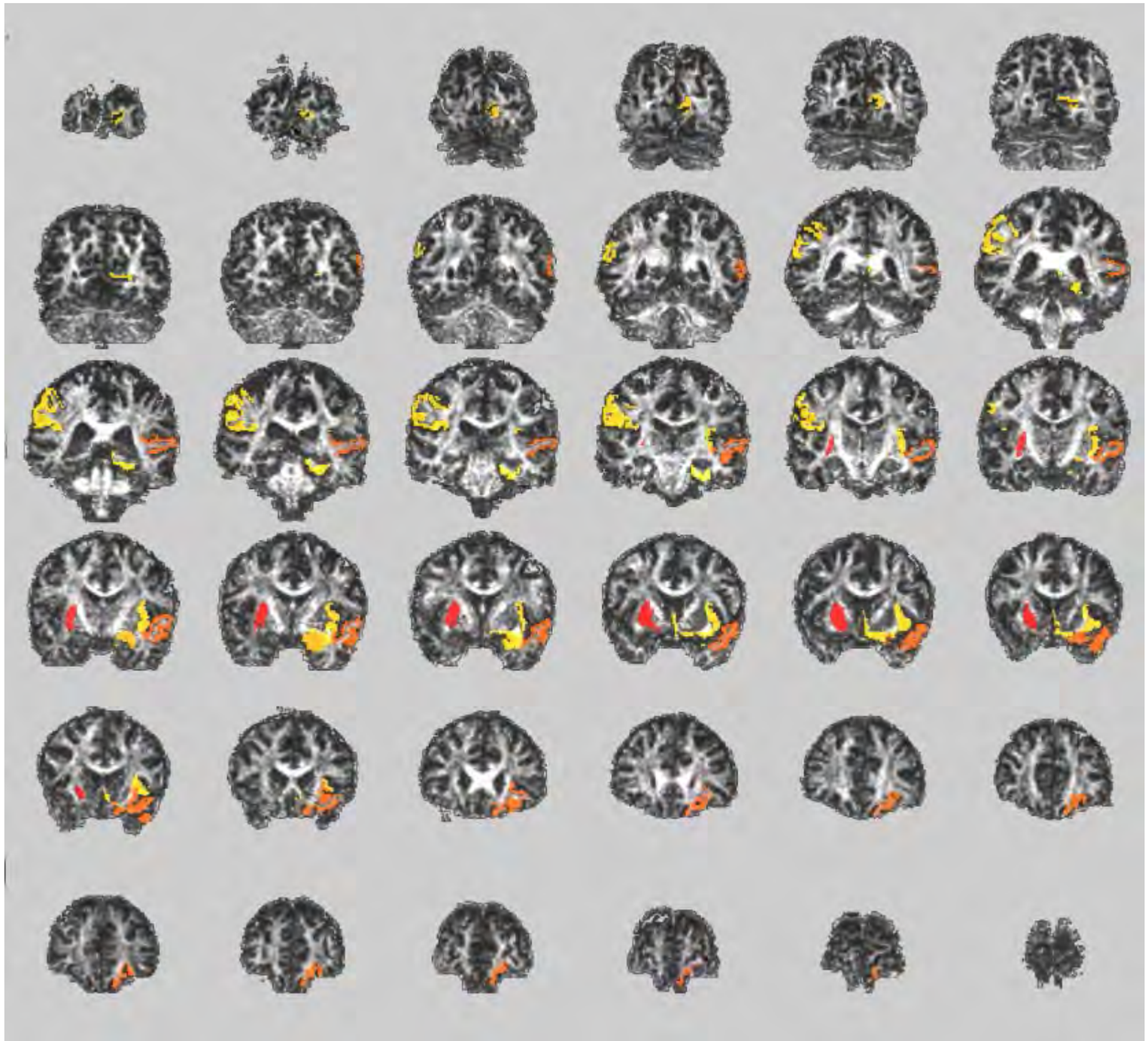

- We wanted to assess DTI as a diagnostic tool by building a normative atlas using DTI scans from healthy individuals.
- Comparing DTI scans of subjects with mTBI to the atlas allows us to localize and assess the severity of brain injury.

(Bouix, Pasternak et al., Plos One, 2013)

Summary Maps for Populations

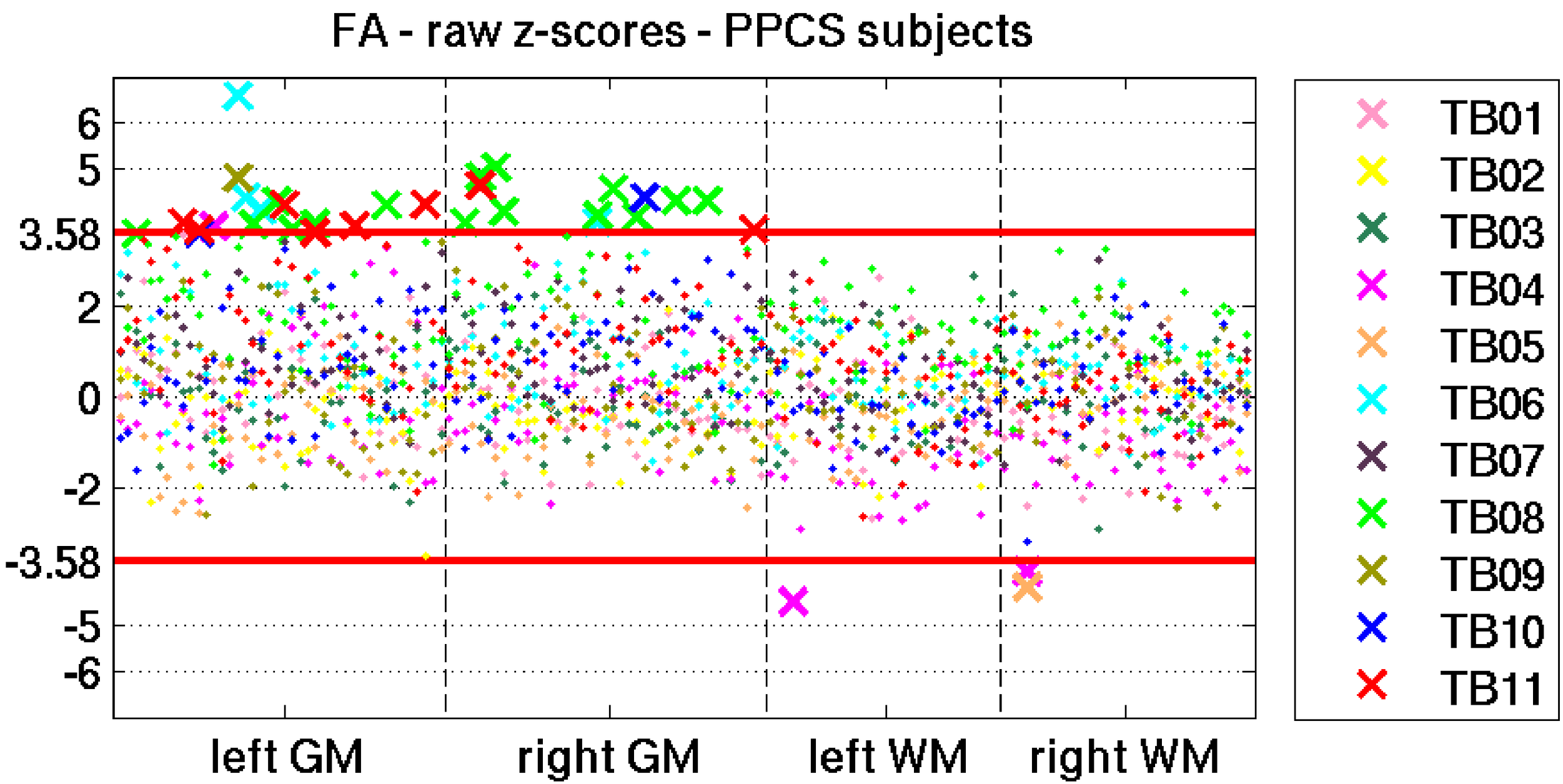

(Bouix, Pasternak et al., Plos One, 2013)

Summary Maps for Populations

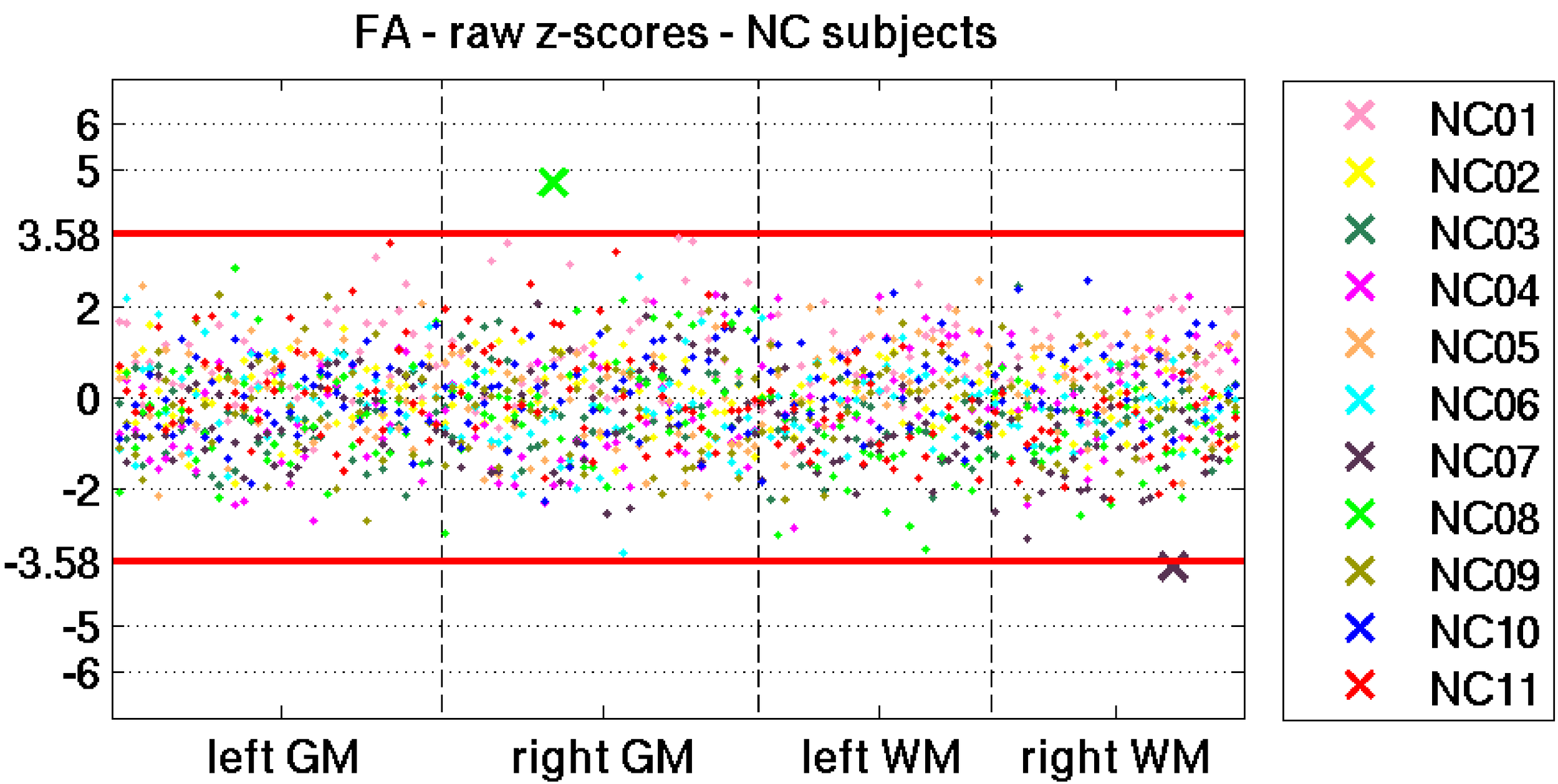

(Bouix, Pasternak et al., Plos One, 2013)

Using DTI Profiles to Guide TDCS

Using Individual DTI Profiles of Mild TBI to Guide Targeted, Non-Invasive Brain Stimulation Intervention for Veterans with Persistent Post-Concussion Symptoms

PI: Elisabeth Wilde, Co-PI: Sylvain Bouix

Begins October 2014

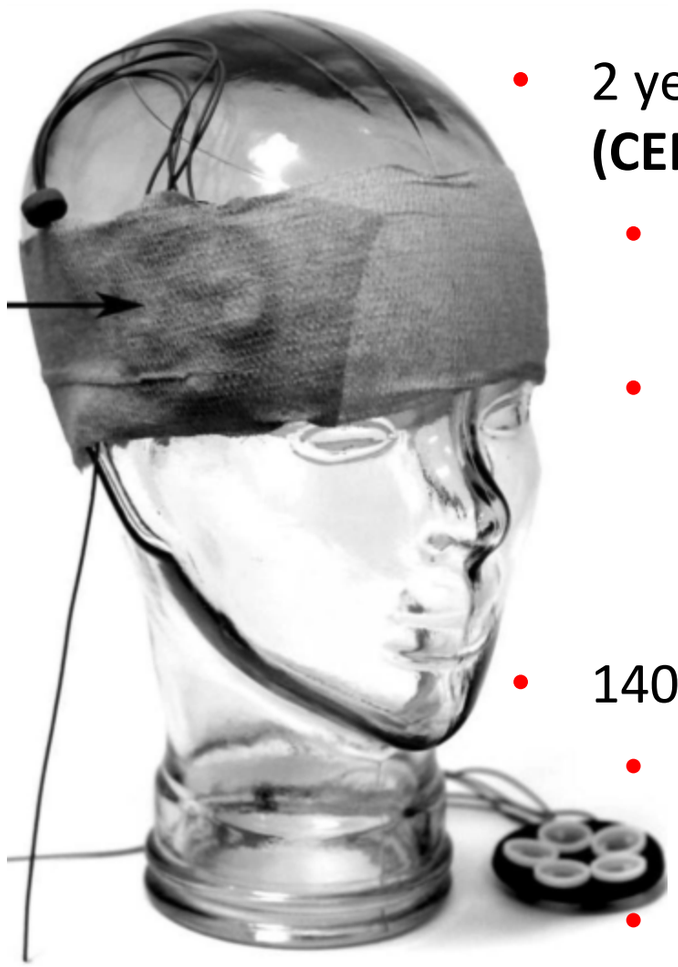

- 2 year proposal funded by the **Chronic Effects of Neurotrauma Consortium (CENC)**
  - **Aim 1:** Create a ***Brain Reference Atlas of Normative Values*** from Healthy Controls.
  - **Aim 2:** Use Individual Subject-Specific Profile of Injury to ***Guide The Targeted Application of Transcranial Direct Conduction Stimulation*** for each Individual and <u>look at change in individual profile of injury following treatment, compared to sham treatment</u>.
- 140 participants (40 mTBI, and 30 controls at each of 2 sites)
  - San Antonio Polytrauma System of Care and South Texas Veterans Health Care System
  - Michael E. DeBakey Veterans Administration Medical Center in Houston

Targeted, Non-Invasive Brain Stimulation Intervention

TDCS Development
M. Weisand (Wright Institute)

DTI Atlas Construction (BWH)
S. Bouix
M. Shenton
Imaging RA

Data Collection
MEDVAMC:
E. Wilde
D. Menefee
RA 1
SAMMC:
G. York
D. Tate
SA VA:
B. Eapen
C. Juarmillo
RA 2

Imaging Analysis
S. Bouix
M. Shenton
D. Tate

Co-Principal Investigators
E. Wilde
S. Bouix

Statistical Analysis
M.J. Pugh (SA VA)

Data Integration and Review
Project Members: E. Wilde, S. Bouix, M. Shenton, D. Tate, M. Weisand, MJ Pugh, B. Eapen, C. Juarmillo
Consultants: E. Bigler, G. York,

- **Diffusion Tensor Imaging and Mild Traumatic Brain Injury**

Sports Concussions

Professional Football: Cortical thickness

Pronounced cortical thinning with age in former professional football players

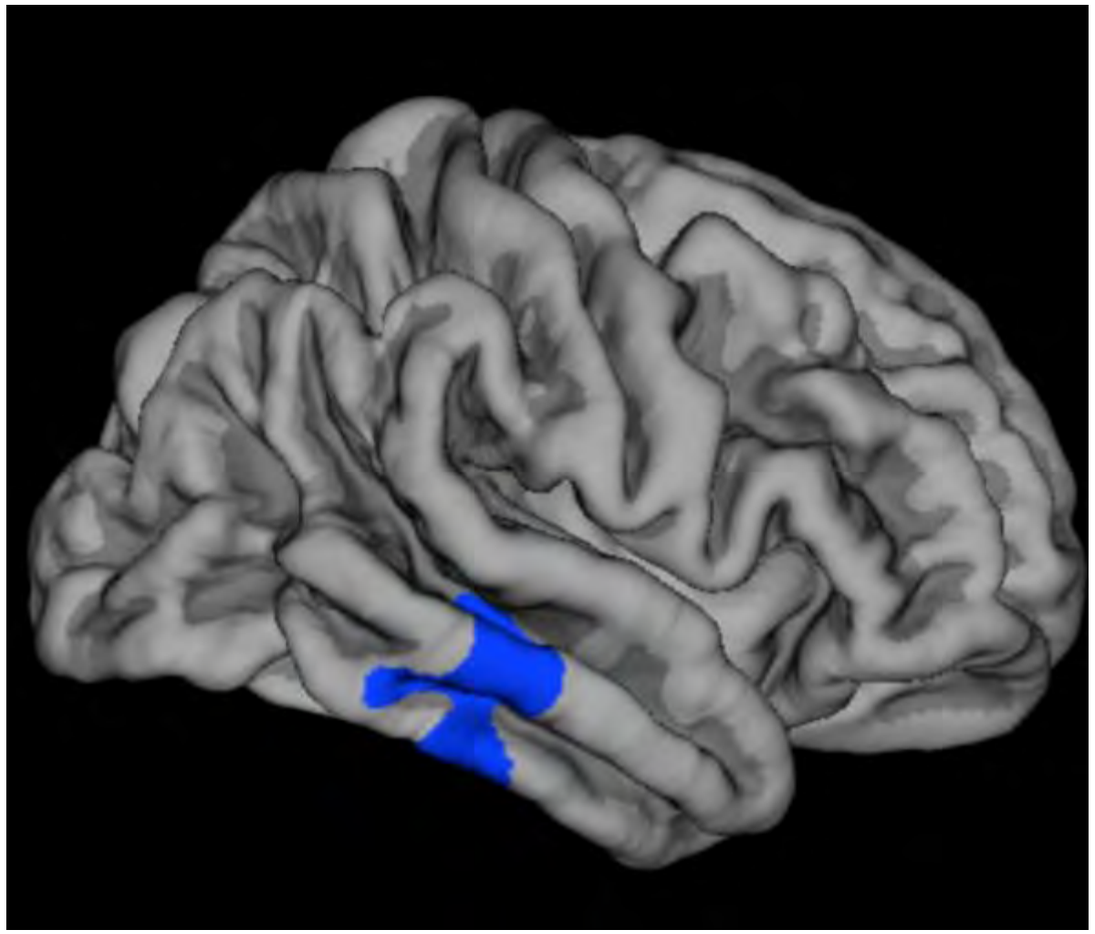

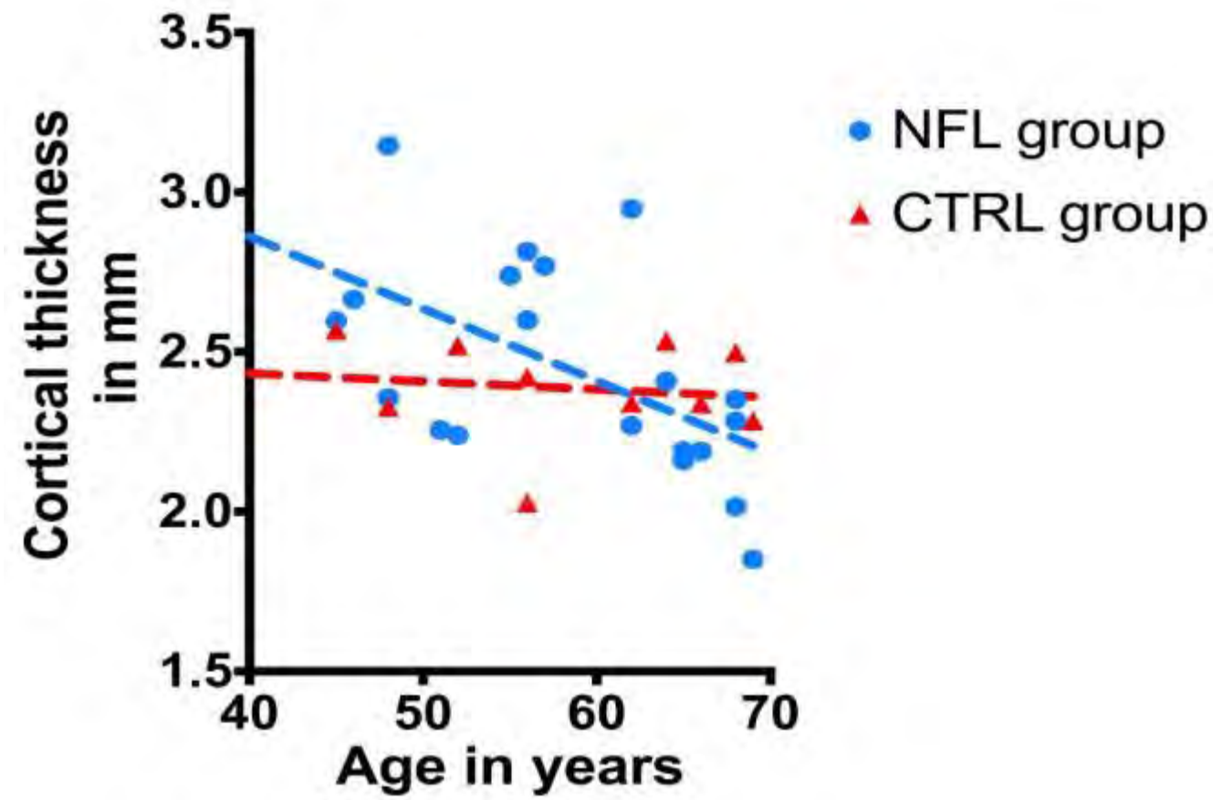

(Koerte et al., in preparation)

- Comparison between former professional football players and athlete controls.
- NFL players show pronounced cortical thinning with increasing age.
- Cortical thinning may indicate abnormal aging and risk for dementia.

Ice Hockey: Diffusion Tensor Imaging

Abnormalities in the brain's microstructure in ice Hockey players

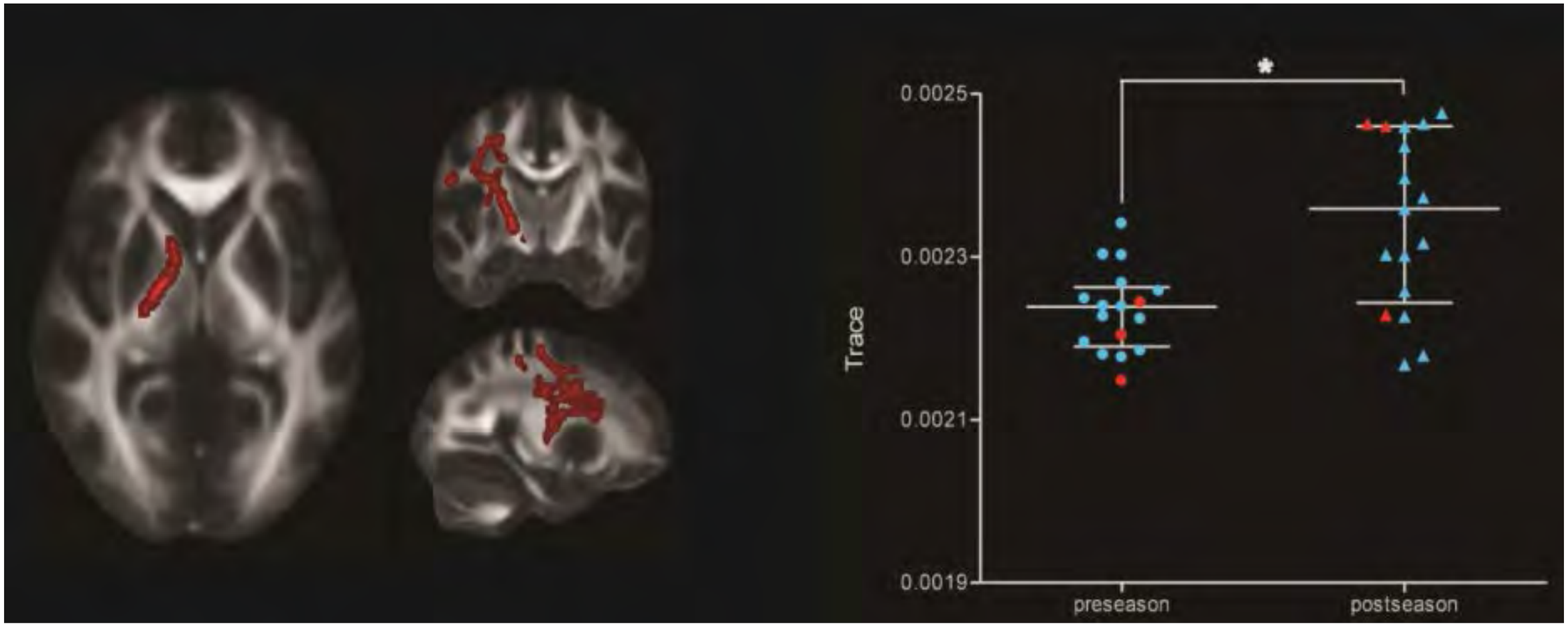

(Koerte et al., Neurosurg Focus 2012)

- Preseason versus postseason evaluation.
- Postseason scans show higher mean diffusivity – more space between axons.
- Participants who suffered from concussion during the season are in red.

Soccer: Brain Changes Following *Sub*concussion

Abnormalities in Soccer Players without history of concussion

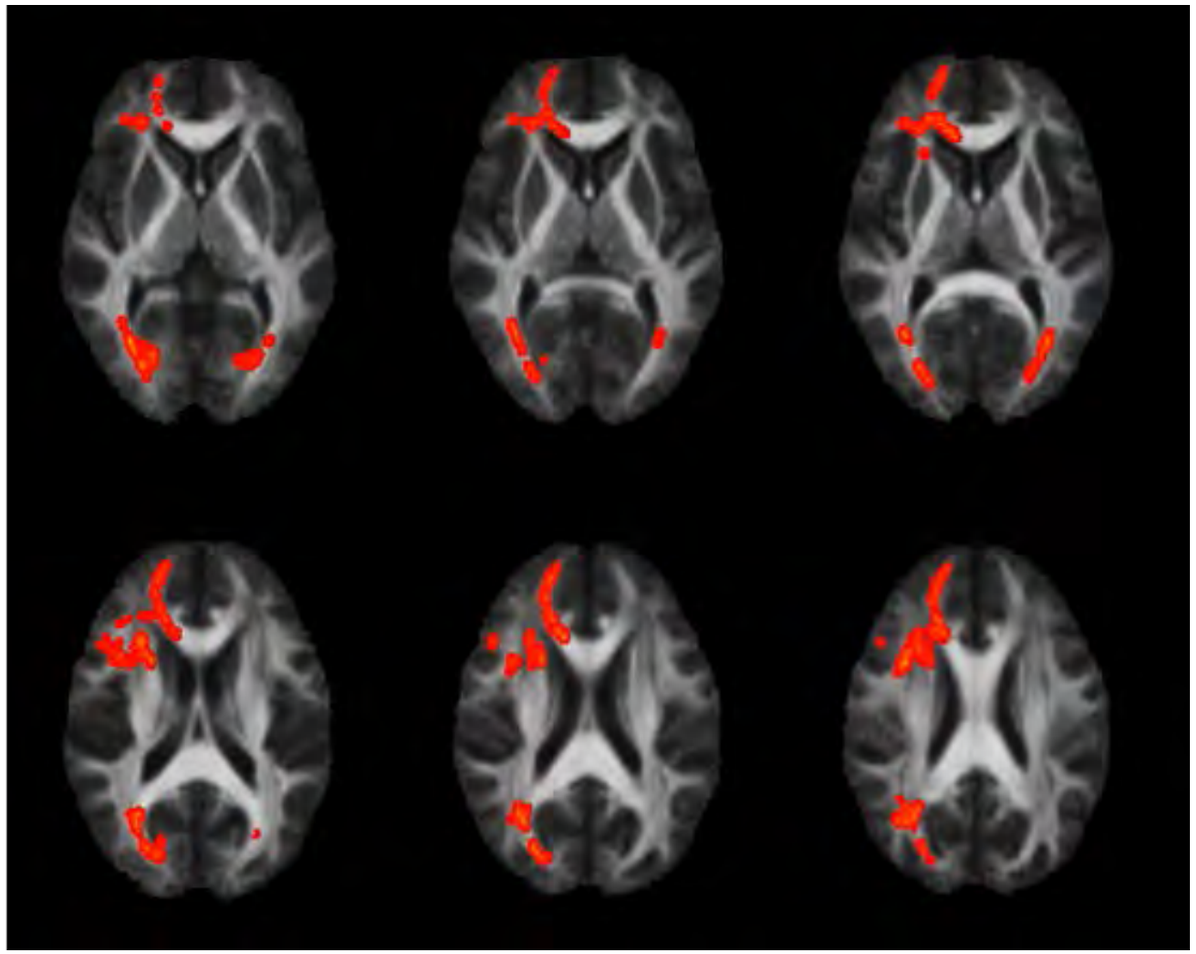

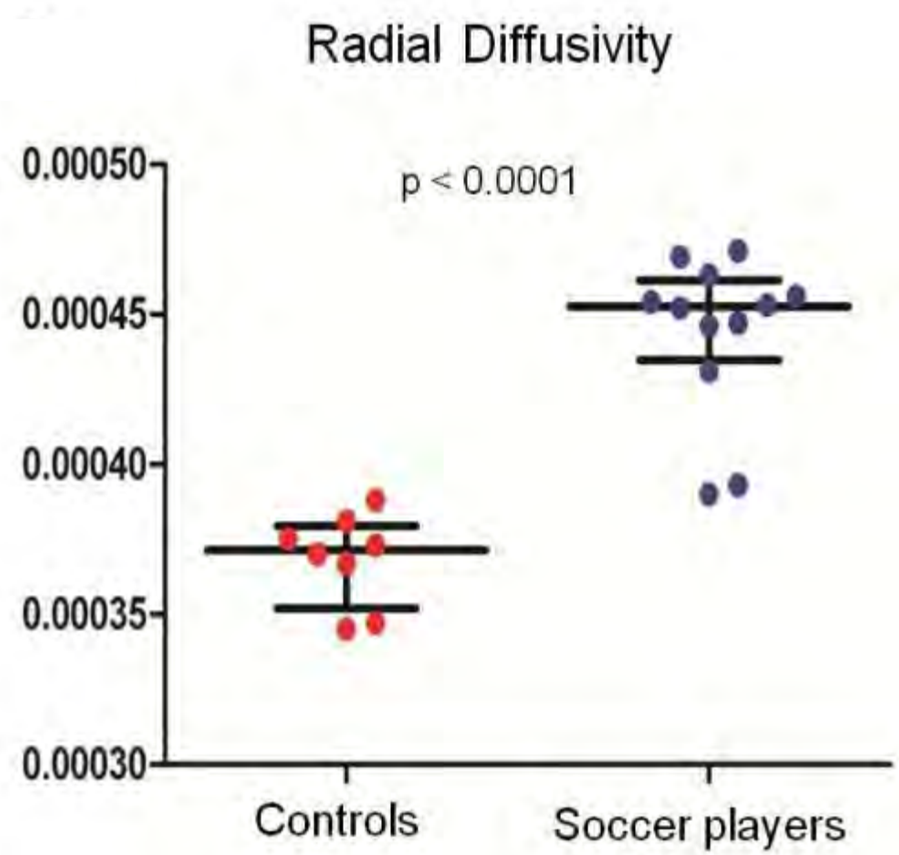

- Elite soccer players versus swimmers.
- Soccer players show higher radial diffusivity – reduced myelin sheath.

(Koerte et al., JAMA 2012)

- **Measuring Tissue Properties with MR**

MR Spectroscopy: The Virtual Biopsy

MR Spectroscopy: The Virtual Biopsy

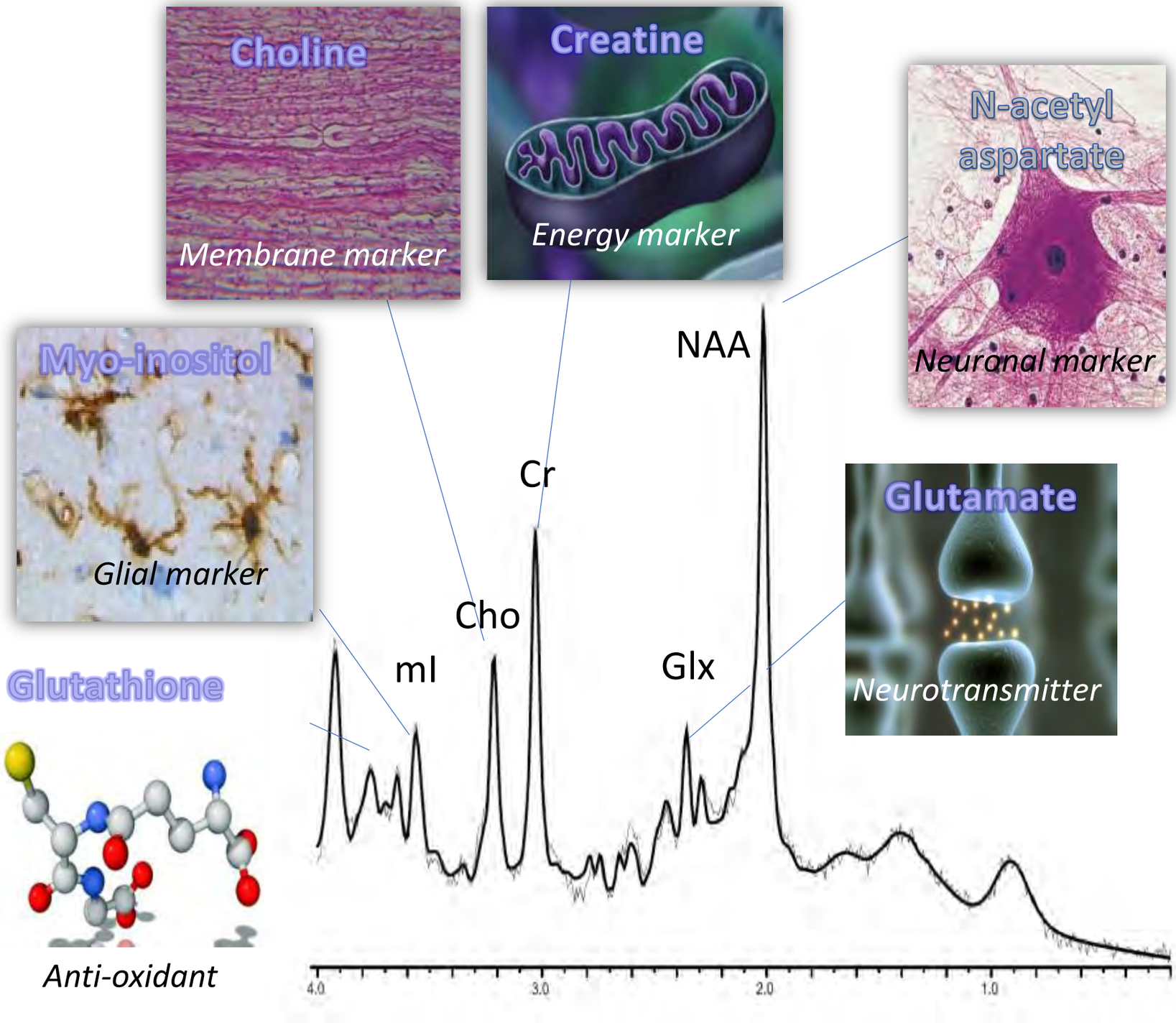

(Alex Lin)

Metabolite Profiles in Chronic Sports-Related Concussion

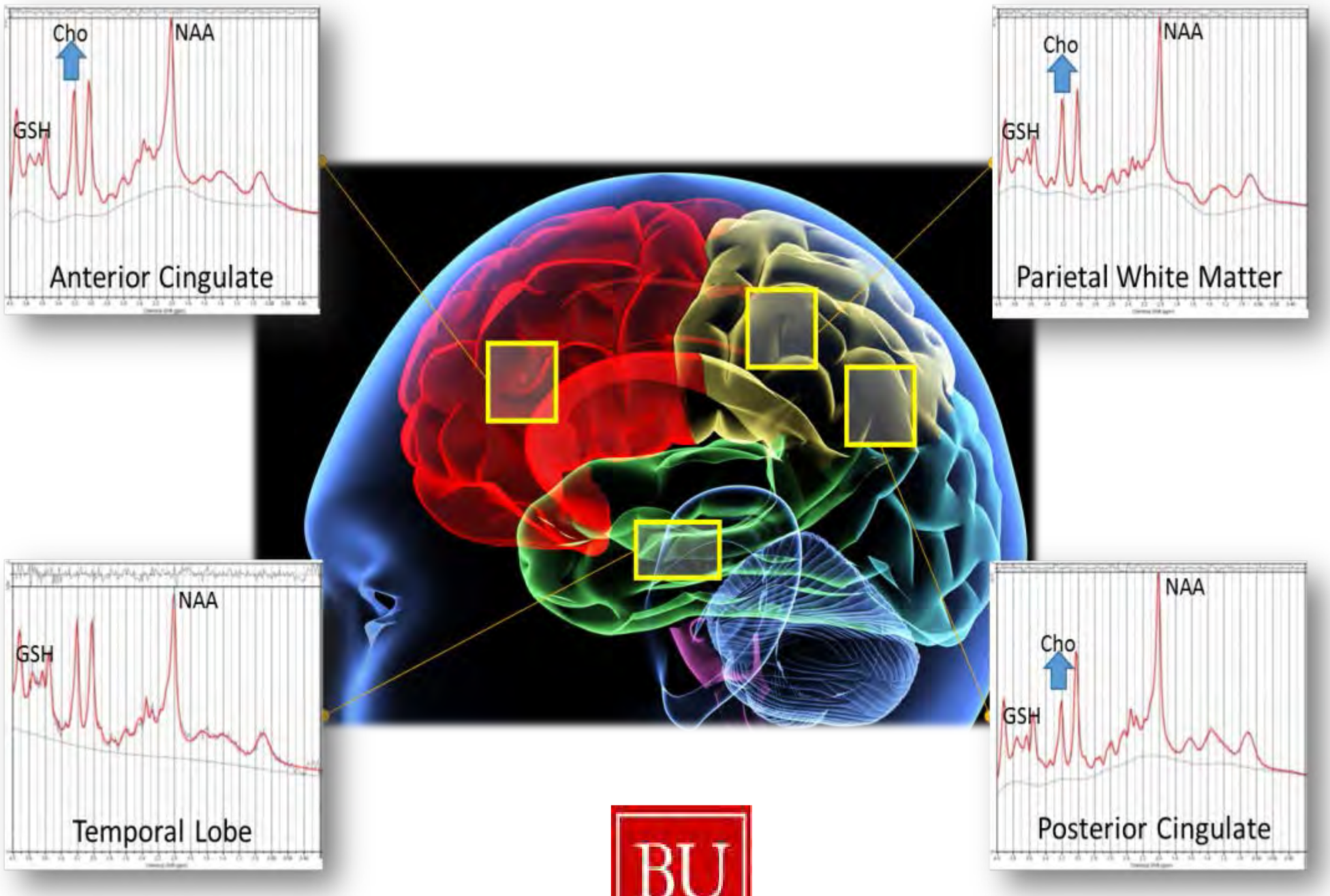

(Alex Lin)

Future Work

Development of MR Biomarkers of Brain Injury in Acute and Chronic mTBI

PI: Martha Shenton, Ph.D. **ORG:** BWH and VA Boston Healthcare System

HSR&D VA Merit (2014-2018)

- Identify those most at risk for developing persistent post-concussive symptoms (PPCS).
- Chart the normal course of recovery versus the development of PPCS in a **longitudinal** (1 week, 3 months, 6 months) **multi-modal imaging study *(MRI/MRS)*** in a sample of acute mTBI patients.
- N=48 acute mTBI patients and 30 orthopedic controls recruited from the BWH ED over 4 years beginning in July 2014.
- Identify imaging biomarkers of injury in 48 mTBI Veterans with PPCS (50% blast vs non-blast injuries) compared with 48 mTBI Veterans without PPCS, and 48 Veteran controls. Data from Veterans has already been acquired using identical MRI sequences. **TRACT STUDY VA BOSTON HEALTHCARE SYSTEM**
- Compare imaging biomarkers of PPCS in acute and chronic samples to determine if there is a similar profile that predicts recovery versus non-recovery from mTBI.

- **Measuring Tissue Properties with PET**

CT, MRI, AND PK11195 Images for a Complicated mTBI Patient and a Healthy Control Subject

22 yo female pedestrian struck by car, with loss of consciousness

Right inferior frontal contusion and small right frontal SDH on CT scan

Initial CT

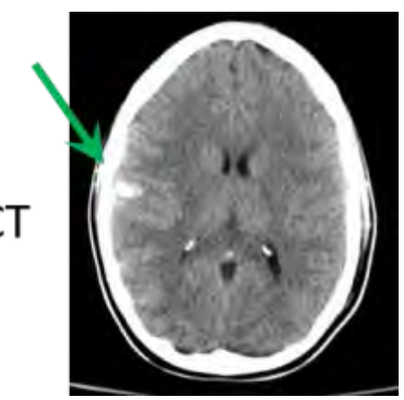

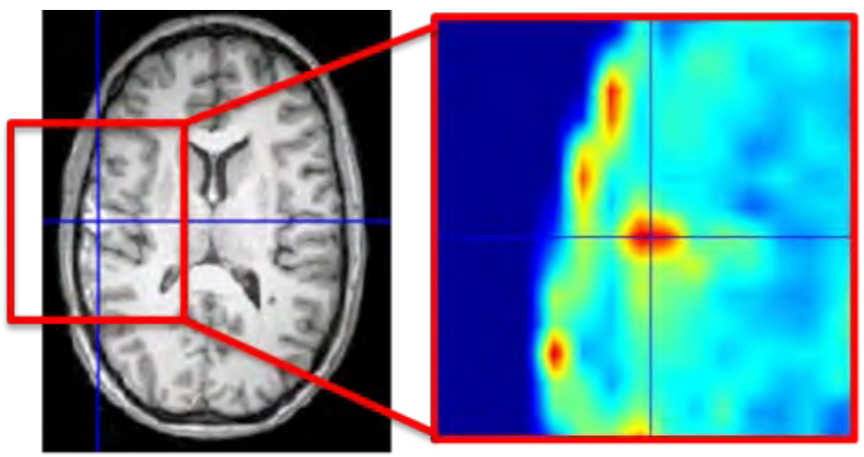

MRI

^{11}C-PK11195 PET Vt map

3/20/13

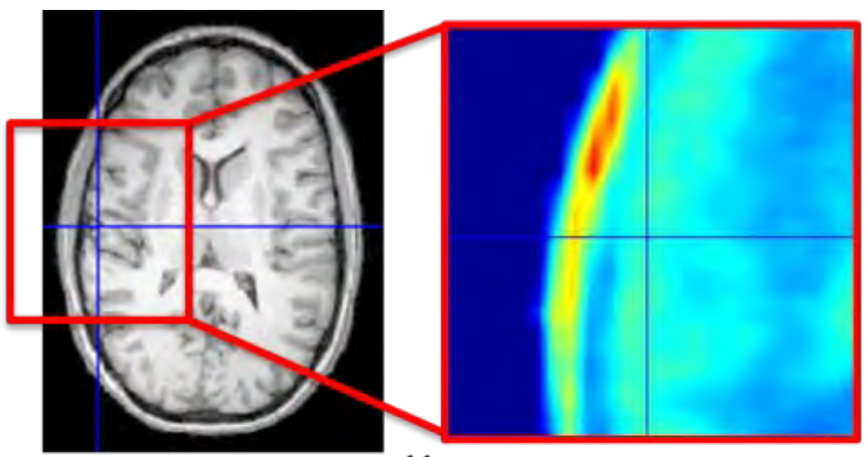

MRI

^{11}C-PK11195 PET Vt map

6/4/13

Healthy Control

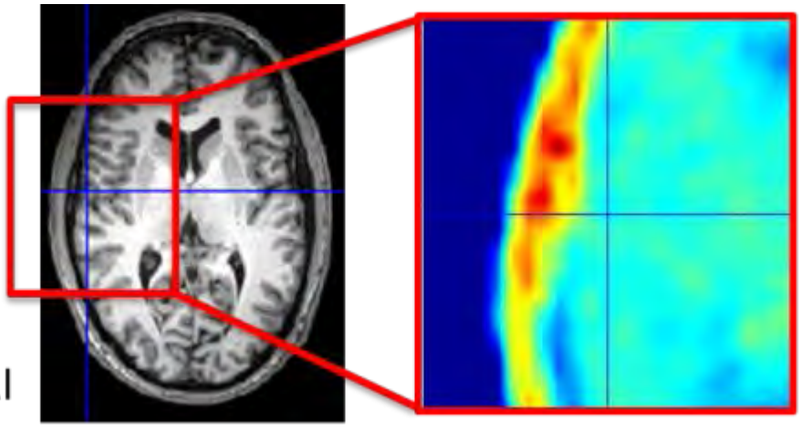

MRI

^{11}C-PK11195 PET Vt map

22 yo female pedestrian struck by car, with loss of consciousness

Right inferior frontal contusion and small right frontal SDH on CT scan

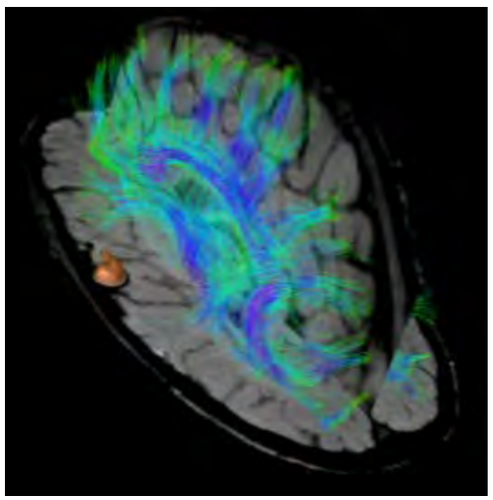

Initial CT

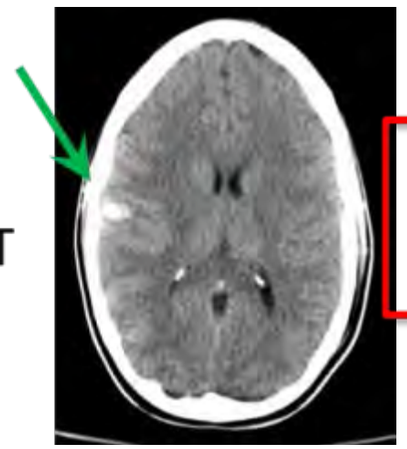

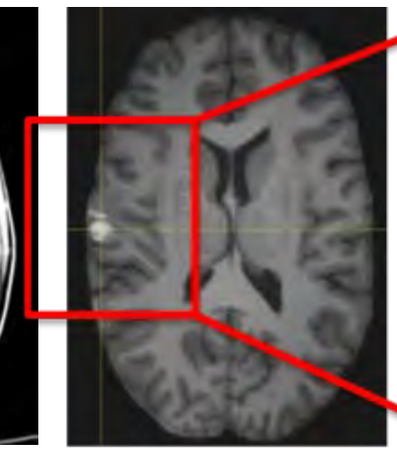

MRI

3/20/13

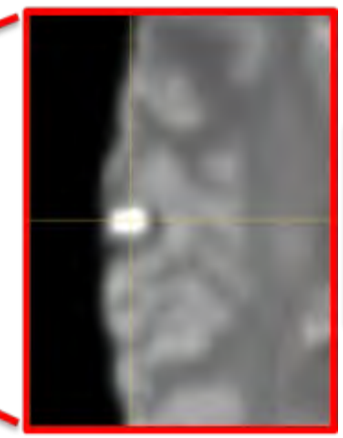

DWI

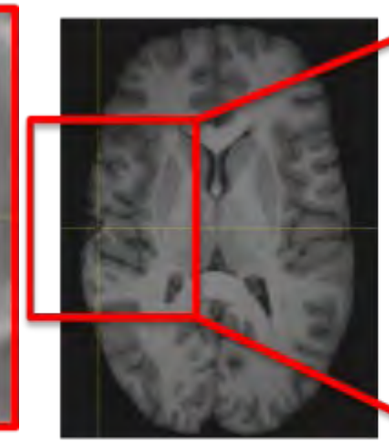

MRI

6/12/13

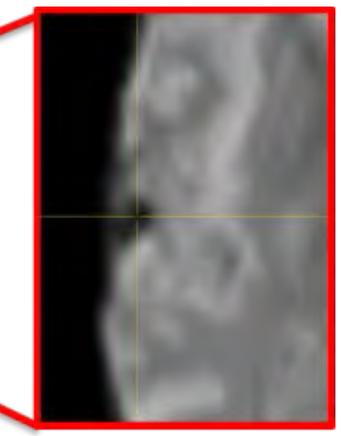

DWI

Healthy Control

3/19/14

MRI

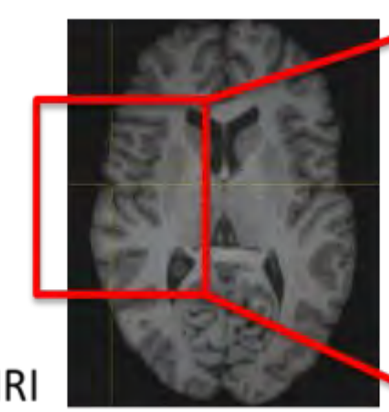

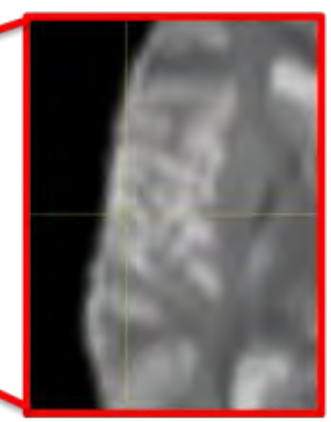

DWI

- **Measuring Tissue Properties with PET**

Tau Imaging in Presumed Chronic Traumatic Encephalopathy

Post-Mortem Tauopathy in a Professional Football Player

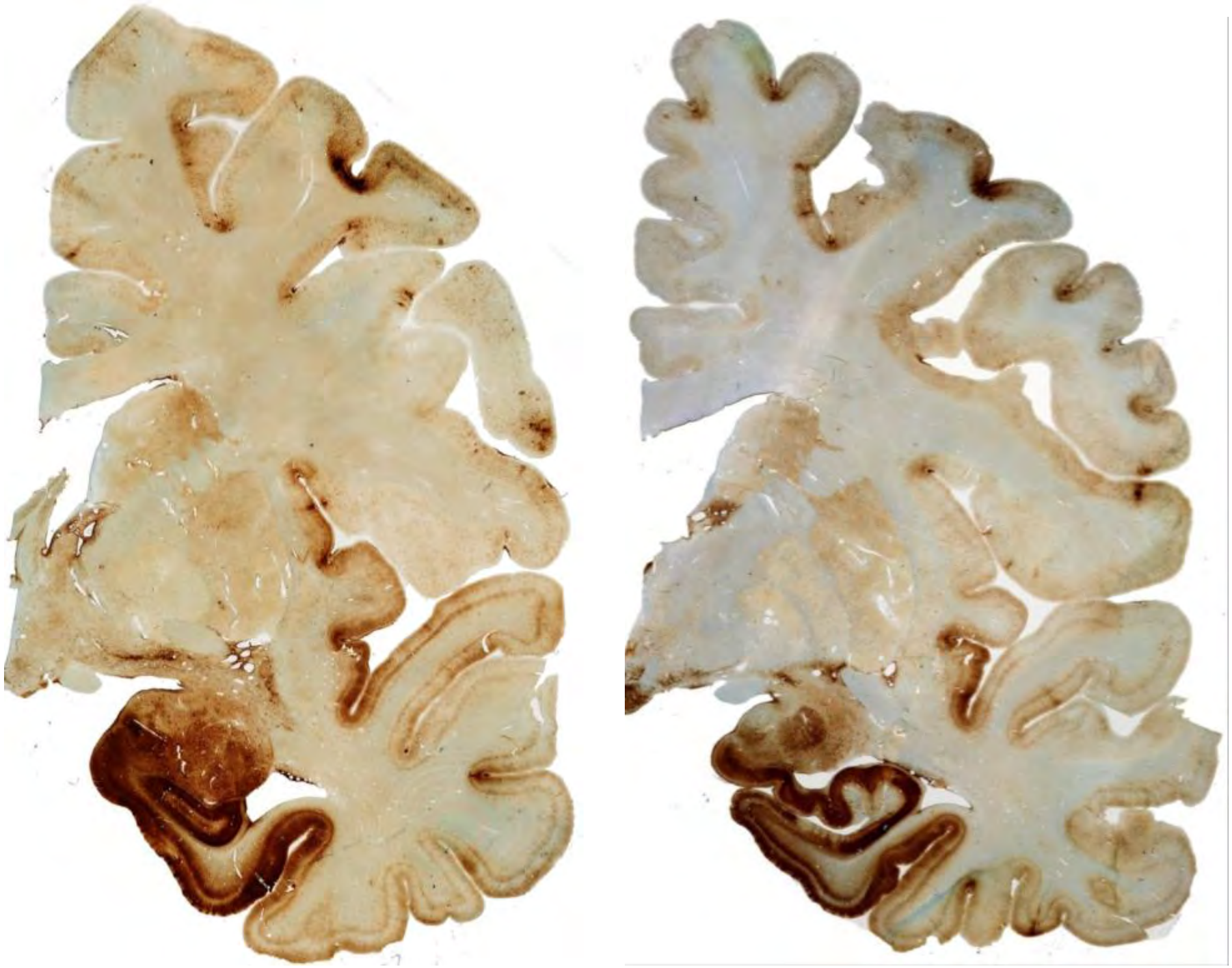

(Ann McKee et al., 2009)

CTE and Blast Injury

Military Blast Injury

Sports-related Injury

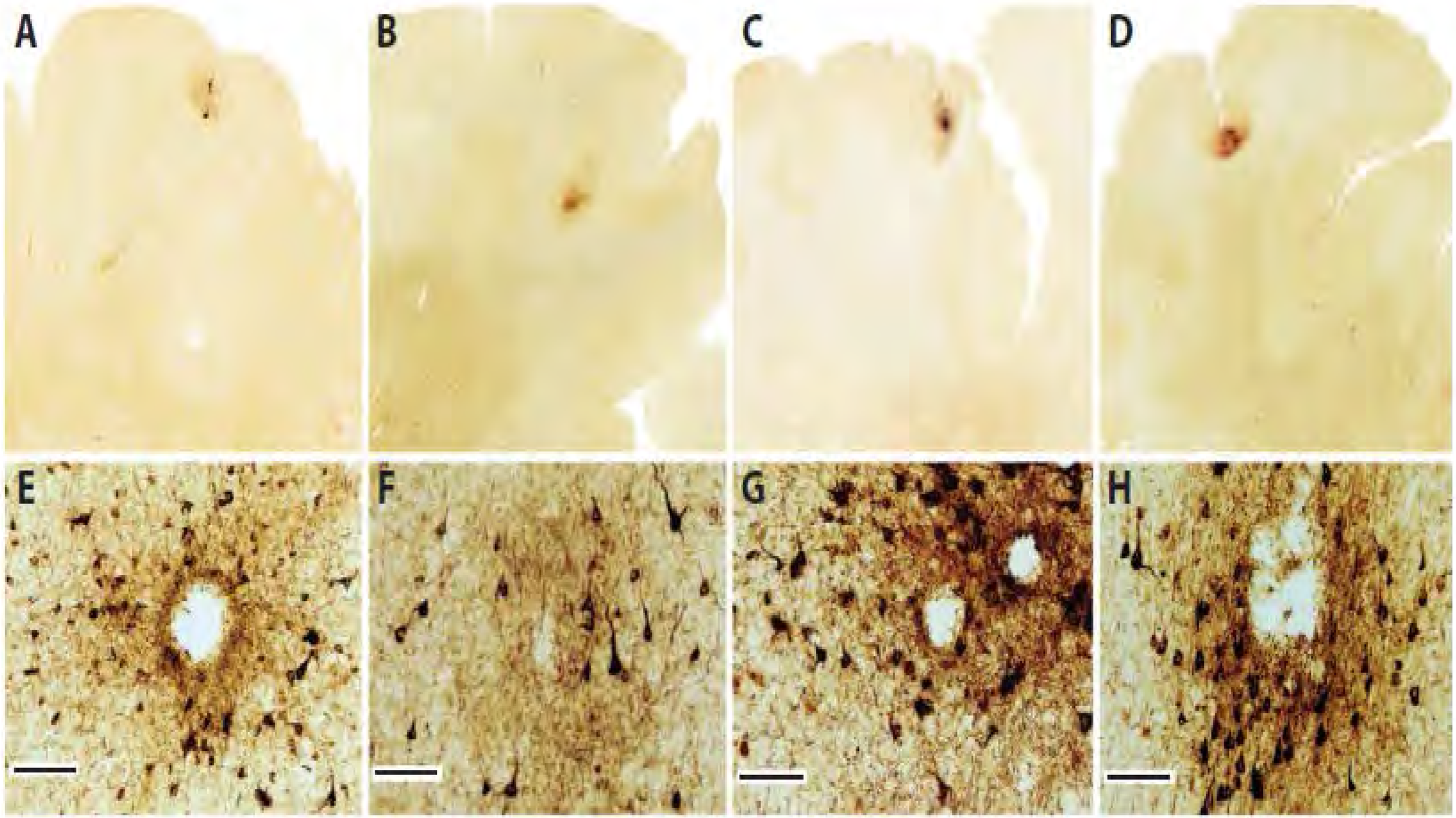

From Goldstein et al. Science Trans Med 2012

New Promise of Tau PET Imaging

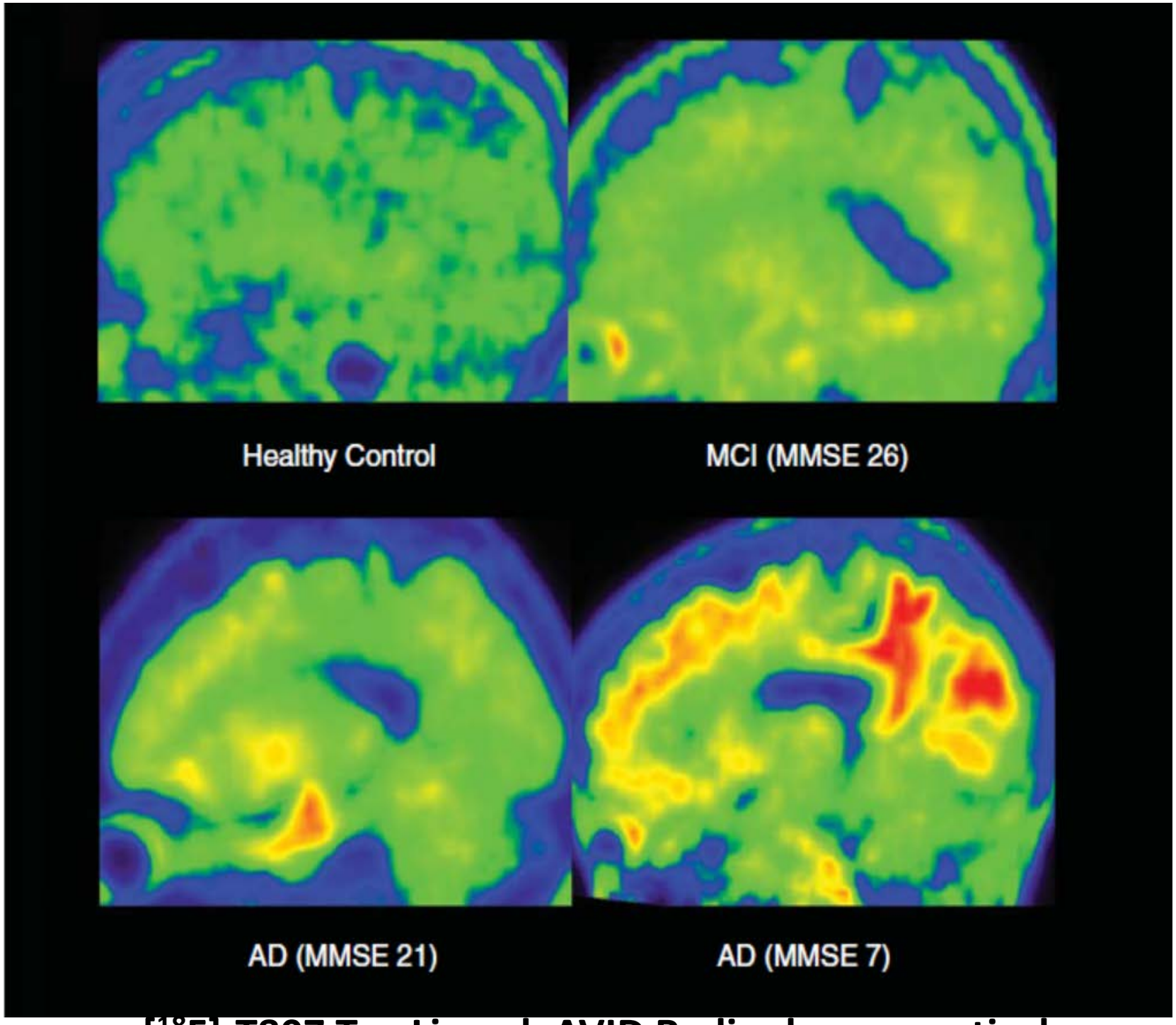

[^{18}F]-T807 Tau Ligand, AVID Radiopharmaceuticals

Next Step PET in Humans

- Rule out Alzheimer's Disease (AD) in suspected CTE.

- Rule in Tauopathy in CTE – the Holy Grail. Positive *in vivo* tau imaging (paired helical filament Tau) using new PET Tau ligand from Siemens.

- Predictions: Amyloid-Beta retention in AD, but not in CTE or in controls (Florbetapir), and Tau retention in AD and in CTE but not controls (Tau; see table, below).

	AD	CTE	Control
Florbetapir	+	--	--
Tau	+	+	--

- **Animal Studies**

CIMIT Animal Models of mTBI

Rat Brain White Matter Analysis

CIMIT®
Center for Integration of Medicine & Innovative Technology

- Analysis pipeline (TBSS) for humans was adapted in order to allow for analyzing rat brains.
- Results show increases in FA in the injured animals.
- Increased FA values were pronounced in the brain stem, lower and anterior parts of the injured rat's brain.

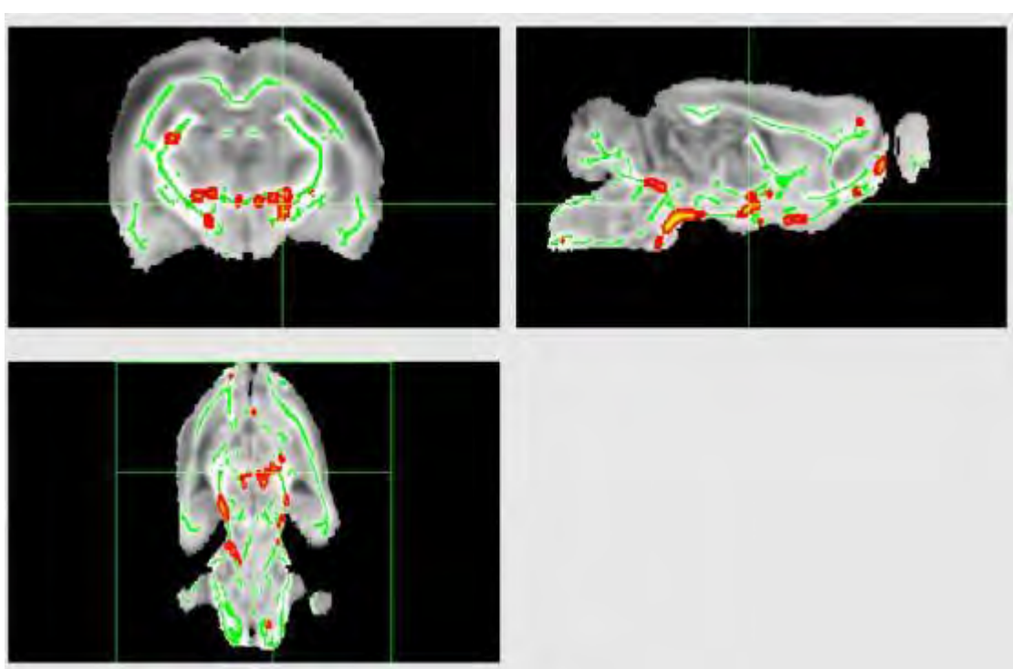

Localized changes in FA to the brain stem, lower and anterior parts of the brain

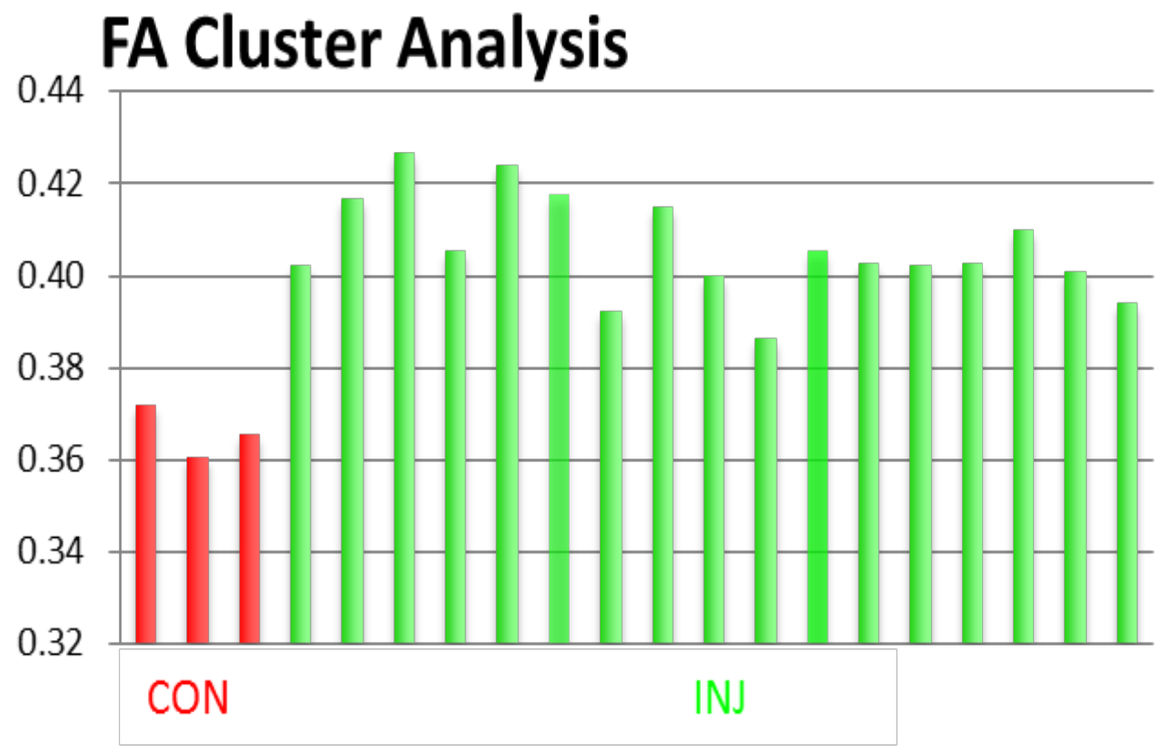

The injured rats showed higher FA

TBI Collaborators

- ***Spaulding Rehabilitation Hospital:*** Ross Zafonte, Grant Iverson.
- ***Sports-Related Injuries:*** Robert Stern (*Boston University*), Inga Koerte, Maximilian Reiser, Birgit Ertl-Wagner (*University of Munich*), Alex Lin (*Brigham and Women's Hospital/Harvard*), Grant Iverson (*University of British Columbia*), Paul Echlin (*The Elliott Sports Medicine Clinic, Ontario, Canada*).
- ***INTRuST Collaborators:*** Murray Stein, Ariel Lang (*UCSD*), Ross Zafonte (*MGH*), Howard Eisenberg (*U Maryland*), Connie Duncan (*USHS*), Gerry Grant (*Stanford*), Tom McAllister (*IUPUI*), Mark George (*USC*), Christine Marx (*Duke*).
- ***Military/Veterans Collaborators:*** Regina McGlincey, William Milberg (*Boston VA*), David Tate, Gerry York (*San Antonio Brooke Army Medical Center*), Carlos Jaramillo, Mary Jo Pugh, Blesen Eapen (*San Antonio VA*), Maulik Purohit (*National Intrepid Center of Excellence, Fort Belvoir*), Elisabeth Wilde, Deleene Menefee (*Michael E. DeBakey VA*).
- ***The Wright State Research Institute:*** Michael Weisend.

Collaborators

Thank you for your attention!

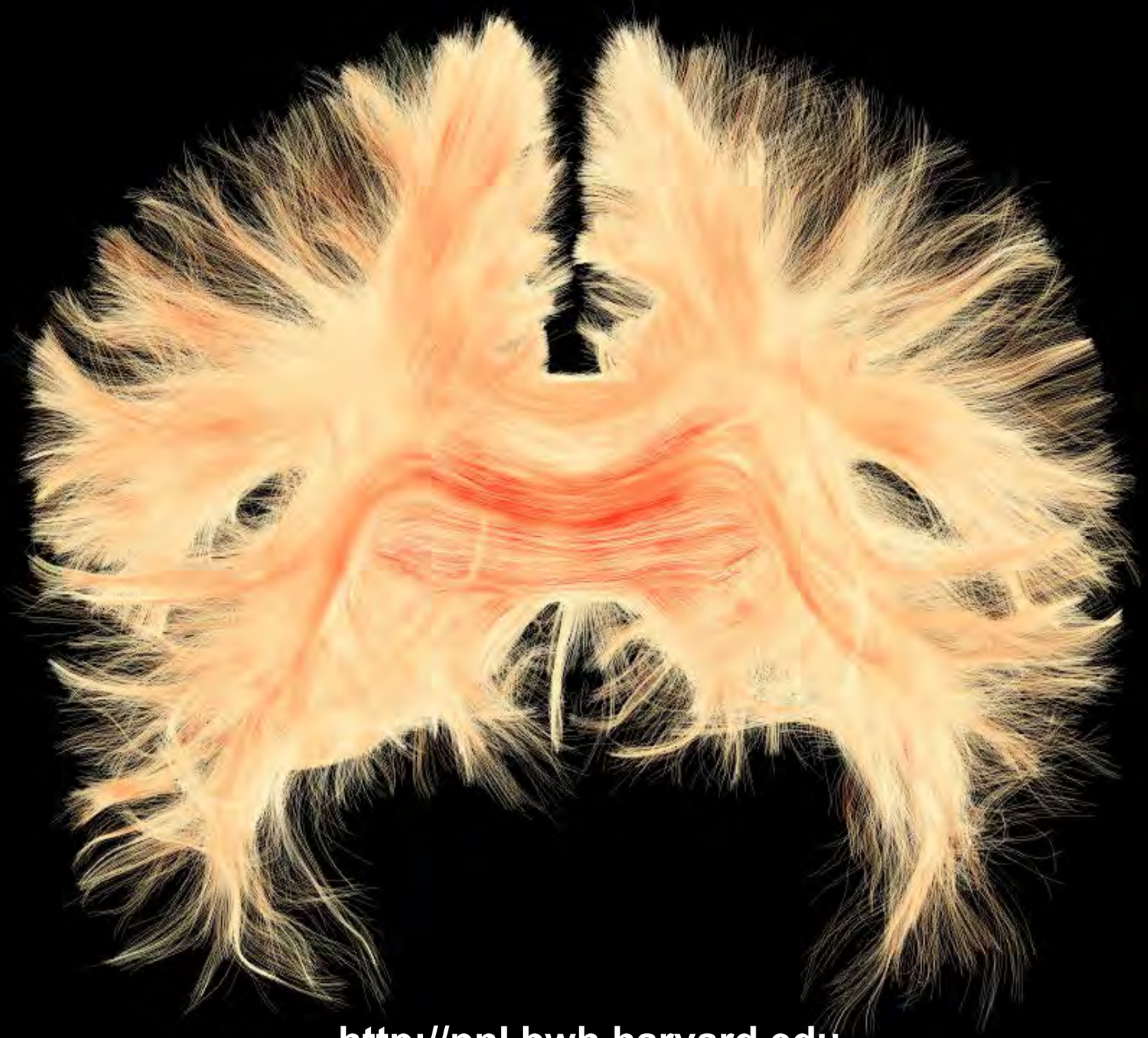

http://pnl.bwh.harvard.edu

Questions/Comments?

Contact Information

Martha E. Shenton, Ph.D.
(shenton@bwh.harvard.edu or
martha.shenton@va.gov)

Website

http://pnl.bwh.harvard.edu/

Acknowledgment of Grant Support

- **Tau Imaging of Chronic Traumatic Encephalopathy** (DoD: W81XWH-13-2-0063: **PI: Martha Shenton, Partnering PI: Robert Stern**).
- **Chronic Traumatic Encephalopathy: Clinical Presentation and Biomarkers** (R01 NS 078337: **PI: Robert Stern**; **Site PI: Martha Shenton**).
- **Posttraumatic Stress and Traumatic Brain Injury Clinical Consortium – INTRuST** (DoD: W81XWH-07-CC-CS: **Overall PI: Murray Stein**, **Site PI: Ross Zafonte, Neuroimaging Core PI: Martha Shenton**, **Ron Kikinis**, **Bruce Rosen**; **Site Pilot PI: Martha Shenton**: PET PK1195 in complicated mTBI; **Site PI: Martha Shenton**: Gylburide Study of Severe TBI; **Site PI: Martha Shenton**: Brain Indices Study**; Site PI: Yogesh Rathi**: Harmonizing DTI Data Across Sites).
- **Identifying Biomarkers that Distinguish Post-Traumatic Stress disorder and Mild Traumatic Brain Injury Using Advanced Magnetic Resonance Spectroscopy** (DOD: 0W81XWH-10-1-0785: **PI: Alex Lin**).
- **Center for Integration of Medicine and Innovative Technology** (CIMIT): Soldiers Award **PI: Sylvain Bouix**.
- **Center for Integration of Medicine and Innovative Technology** (CIMIT): Innovative Grant **PI: Alex Lin**.
- **Development of MR Biomarkers of Brain Injury in Acute and Chronic mTBI** (VA Merit Award: **PI: Martha Shenton**).
- **Improving Imaging and Diffusion Axonal Injury in Traumatic Brain Injury** (CIMIT: PI: **Martha Shenton**, **Co-PI: Bruce Kristal**).
- **Frontal Lobe Neuroimaging as a Biomarker of CTE** (National Research Service Award for Independent Pre-Doctoral Fellow, F31 NS 081957: **PI: Julie Stamm**: **Co-Mentors: Robert Stern** and **Martha Shenton**).

Our Publications, Proceedings, & Presentations

TBI Reviews, Journal Papers, Methods Papers, & Presentations (*= Current or Former Trainee)

REVIEWS AND JOURNAL PAPERS

- Gavett BE, Cantu RC, Shenton M, *Lin AP, McKee AC, Stern RA. Clinical appraisal of chronic traumatic encephalopathy: Current perspectives and future directions. *Current Opinion in Neurology* 2011;24:525-531. PMID: 22045219

- ➔➔Shenton ME, *Hamoda HM, *Schneiderman JS, *Bouix S, *Pasternak O, *Rathi Y, *Vu M-A, *Purohit MP, Helmer K, *Koerte I, *Lin AP, Westin C-F, Kikinis R, Kubicki M, Stern RA, Zafonte R. A review of magnetic resonance imaging and diffusion tensor imaging findings in mild traumatic brain injury. *Brain Imaging and Behavior* 2012;6(2):137-192. **(Most Downloaded Article for this Journal)** PMID: 22438191

- *Tate DF, Shenton ME, Bigler ED. Introduction to the brain imaging and behavior special edition on neuroimaging findings in mild traumatic brain injury. *Brain Imaging and Behavior* 2012;6(2):103-107. PMID: 22706729

- Baugh CM, *Stamm JM, Riley DO, Gavett BE, Shenton M**E**, *Lin A, Nowinski CJ, Cantu RC, McKee AC, Stern RA. Chronic traumatic encephalopathy: neurodegeneration following repetitive concussive and subconcussive brain trauma. *Brain Imaging and Behavior* 2012;6(2):244-254. PMID: 22552850

Our Publications, Proceedings, & Presentations

- ➔➔*Koerte IK, Ertl-Wagner B, Reiser M, Zafonte R, Shenton ME. White matter integrity in the brains of professional soccer players without a symptomatic concussion. *JAMA* 2012;308(18):1859-1861. PMID: 23150002

- *+Koerte IK, +Kaufman D, Hartl E, *Bouix S, *Pasternak O, *Kubicki M, Rauscher A, Li DK, Dadachanji SB, Tauton JA, Forwell LA, Johnson AM, Echlin PS**, Shenton ME**. A prospective study of physician-observed concussion during a varsity university hockey season: White matter integrity in ice hockey players. Part 3 of 4. *Neurosurgery Focus (JNS)* 2012;33(6):E3. (+Denotes equal first authorship.) PMID: 23199426 [full text]

- *Pasternak O, Westin C-F, *Bouix S, Seidman LS, *Goldstein JM, Woo T-U, Petryshen TL, Mesholam-Kately RI, McCarley RW, Kikinis R, Shenton ME, *Kubicki M. Excessive extracellular volume reveals a neurodegenerative pattern in schizophrenia onset. *J Neurosci* 2012;32(48):17365-17372. PMID: 23197727 (**Figure featured in this week in the journal**).

- *+Koerte IK, +Kaufman D, Hartl E, *Bouix S, *Pasternak O, *Kubicki M, Rauscher A, Li DK, Dadachanji SB, Tauton JA, Forwell LA, Johnson AM, Echlin PS, Shenton ME. A prospective study of physician-observed concussion during a varsity university hockey season: White matter integrity in ice hockey players. Part 3 of 4. *Neurosurgery Focus (JNS)* 2012;33(6):E3. (+Denotes equal first authorship.) PMID: 23199426 [full text]

Our Publications, Proceedings, & Presentations

- *Lin A, Liao HJ, Merugumala SK, Prabhu SP, Meehan WP 3rd, Ross BD. Metabolic imaging of mild traumatic brain injury. Brain Imaging Behav. 2012; 6(2):208-23.

- ➔➔*Bouix S+, *Pasternak O+, *Rathi Y, **Pelavin PE*, *Zafonte R*, *Shenton ME*. Increased gray matter diffusion anisotropy in patients with persistent post-concussive symptoms following mild traumatic brain injury. *PLoS ONE* 2013;8(6):e66205. (+Denotes that authors contributed equally to this work.)

- *Pasternak O, *Koerte I, **Bouix S*, **Fredman E*,* Sasaki T, Mayinger M, *Helmer KG*, Johnson AM, Holmes JD, Forwell LA, Skopelja E, Shenton ME+, Echlin P+. Microstructural white matter alterations in acutely concussed ice hockey players, Part 1: a longitudinal free-water study. *J Neurosurg* 2014;120(4):864-72.

- *Pasternak O, *Koerte I, *Bouix S, *Fredman E, *Sasaki T, Mayinger M, Helmer KG, Johnson AM, Holmes JD, Forwell LA, Skopelja E, Shenton ME+, Echlin P+. Micostructural white matter alterations in acutely concussed ice hockey players, Part 1: a longitudinal free-water study. *J Neurosurg* 2014;120(4):873-881. (+denotes dual last authorship)

- *Sasaki T, *Pasternak O, *Mayinger M,*Muelmann M, *Savadjiev P, *Bouix S, *Kubicki M, *Fredman E, *Dahlben B, Helmer K, Johnson AM, Holmes JD, Forwell LA, Skopelja E, Shenton ME, Echlin P+, *Koerte IK+. Changes in white matter microstructure in ice hockey players with a history of concussion: A diffusion tensor imaging study, Part 2: a diffusion tensor imaging study. *J Neurosurg* 2014;120(4):882-990. (+denotes dual last authorship)

Our Publications, Proceedings, & Presentations

- Helmer KG, *Pasternak O, *Fredman E, Preciado R, *Koerte I, *Sasaki T, Mayinger M, Johnson A, Holmes J, Forwell L, Skopelja E, Shenton ME+, Echlin P+. Susceptibility-weighted imaging study in male and female ice hockey players over a single season, Part 3. Clinical article. *J Neurosurg* 2014;120(4):864-873. (+denotes dual last authorship)

- Ng TSC+, Lin AP+, *Koerte IK, *Pasternak O, Liao H, Merugumala S, *Bouix S, Shenton ME. Neuroimaging in repetitive brain trauma. *Alzheimer's Research and Therapy*. (In Press). (+denotes dual first authorship) DOI is 10.1186/alzrt239

- *Koerte I, *Hufschmidt J, *Muehlmann M, Shenton ME. Neuroimaging. In: Laskowitz, Grant (Editors) *Frontiers in Neuroscience - Translational Research in Traumatic Brain Injury*. Taylor & Francis (In Press).

Our Publications, Proceedings, & Presentations

Methods Papers, and Processings: Applied Now to TBI Studies
Journal Papers

- Malcolm JG, Shenton ME, *Rathi Y. Two-tensor tractography using a constrained filter. *Med Image Comput Comput Assist Interv* 2009;12(Pt 1):894-902. PMCID: PMC2893231

- Malcolm JG, Michailovich O, *Bouix S, Westin C-F, Shenton ME, *Rathi Y. A filtered approach to neural tractography using the Watson directional function. *Med Image Anal* 2010;14:58-59. PMID: 19914856

- *Rathi Y, Malcolm J, Michailovich O, Westin C-F, Shenton ME, *Bouix S. Tensor-kernels for simultaneous fiber model estimation and tractography. *Magn Reson Med* 2010;64(1):138-148. PMCID: PMC3043656

- Malcolm J, Shenton ME, *Rathi Y. Filtered multi-tensor tractography. *IEEE Trans Med Imaging* 2010;29(9):1664-1675.PMCID: PMC3045040

- *Rathi Y, Malcolm J, Michailovich O, Goldstein J, Seidman L, McCarley RW, Westin CF, Shenton ME. Biomarkers for identifying first-episode schizophrenia patients using diffusion weighted imaging. *Med Image Comput Comput Assist Interv* 2010;13(Pt 1):657-665. PMCID: PMC3091029

Our Publications, Proceedings, & Presentations

- *Rathi R, *Kubicki M, *Bouix S, Westin C-F, *Goldstein J, Seidman LJ, Mesholam-Gately R, McCarley RW, Shenton ME. Statistical analysis of fiber bundles using multi-tensor tractography: Application to first-episode schizophrenia. *Magn Res Imaging* 2011;29(4):507-15. PMCID: PMC3078978

- *Rathi Y, Michailovich O, Setsompop K, *Bouix S, Shenton ME, Westin CF. Sparse multi-shell diffusion imaging. *Med Image Comput Comput Assisted Interv* 2011;14(Pt 2):58-65. PMID: 21995013

- *Pasternak O, Shenton ME, Westin CF. Estimation of extracellular volume from regularized multi-shell diffusion MRI. *Med Image Comput Comput Assist Interv*. 2012;15(Pt2):305-312. PMID: 23286062

Proceedings

- Malcolm J, Shenton ME, *Rathi Y. Neural Tractography Using An Unscented Kalman Filter. In: *Information Processing in Medical Imaging (IPMI)*, 2009. PMCID: PMC2768602 (Oral presentation.)

- Malcolm J, Shenton ME, *Rathi Y. Filtered Tractography: Validation on a Physical Phantom. In: *Workshop on Diffusion Modeling and Fiber Cup. MICCAI*, 2009. [full text]

Our Publications, Proceedings, & Presentations

- Malcolm J, Shenton ME, *Rathi Y. The Effect of Local Fiber Model on Population Studies. In: *Workshop on Diffusion Modeling and Fiber Cup. MICCAI*, 2009. [full text]

- *Rathi Y, Malcolm JG, *Bouix S, Kindlmann G, Westin C-F, *Kubicki M, Shenton ME. Mixture Model for estimating fiber ODF and multi-directional Tractography. In: *International Society For Magnetic Resonance in Medicine Scientific Meeting* 2009;17:3548. [full text] [PowerPoint]

- *Rathi Y, Malcolm J, *Bouix S, Westin C-F, Shenton ME. Disease Classification: A probabilistic Approach. In: *International Symposium on Biomedical Imaging* 2010;1345-1348. [full text]

- *Pasternak O, *Bouix S, *Rathi Y, Branch C, Westin C-F, Shenton ME, Lipton M. Identification of Mild Traumatic Brain Injuries by Comparison of Free-Water Corrected z-Distributions, *Proceeding of the 21th International Society for Magnetic Resonance in Medicine meeting (ISMRM)*, Salt-Lake City, UT, 2013.

- *Pasternak O, *Bouix S, *Rathi Y, Branch CA, Westin C-F, Shenton ME, Lipton M. Characterization of Diffusion MRI Abnormalities using a Joint Distribution Normative Atlas, *International Society for Magnetic Resonance in Medicine Workshop on Diffusion as a Probe of Neural Tissue Microstructure,* Croatia, 2013.

Our Publications, Proceedings, & Presentations

Chapters in Books

- *Pasternak O, Fritzsche K, Baumgartner C, Shenton M**E**, *Rathi Y, Westin C-F. The estimation of free-water corrected diffusion tensors. In: *Visualization and Processing of Tensors and Higher Order Descriptions for Multi-Valued Data.* (Editors: C-F Westin, A Vilanova, B Burgeth), Springer, Berlin, Germany (In Press).

- *Koerte I, and *Muehlmann, M. Diffusion Tensor Imaging. In: Mulert C, Shenton ME (Editors) *MRI in Psychiatry*. Springer Publishers (In Press).

- *Koerte I, *Lin A, *Muehlmann M, Rauchmann B-S, Cooper K, *Mayinger M, Stern RA, Shenton ME. Post-traumatic cognitive disorders. In: Kanekar Sangam (Ed) *Imaging of Neurodegenerative Diseases*. Thieme Publishers (In Press).

Other

- Shenton ME. Comment on Small et al. paper entitled "PET scanning of brain Tau in retired national football league players: Preliminary findings presented in Am J Geriatric Psychiatry 2013;21:138e144. In *Alzheimer Research Forum*, January 23, 2013 www.alzform.org/pap/annotation.asp?powID=142265

Our Publications, Proceedings, & Presentations

TBI Related Abstracts/Presentions

- *Koerte I, Kaufmann D, *Pelavin P, *Eckbo R, *Rathi Y, Reiser M, *Kubicki M, Heinen F, Shenton M, Ertl-Wagner B. Differentiation of transcallosal motor fibers of the upper and lower extremities in professional soccer players as demonstrated by a two-tensor algorithm. *RSNA*, December, 2011, Chicago, IL (Oral Presentation).

- *Bouix S, *Pelavin P, *Pasternak, *Schneiderman J, *Kubicki M, Zafonte RD, Shenton ME. Diagnosis of Diffuse Axonal Injury with Diffusion Tensor Imaging, *3rd Federal Interagency Conference on TBI*, Washington DC, 2011.

- *Pasternak O, *Kubicki O, *Pelavin P, Zafonte RD, Shenton ME, and *Bouix S. Identification of Neuroinflammation in Mild Traumatic Brain Injuries using a Free-Water Atlas. *Annual Meeting of the Organization for the Human Brain Mapping*, 2011.

- *Pasternak O, *Bouix S, *Kubicki M, *Pelavin P, *Schneiderman J, Zafonte RD, Shenton M**E**. Diffusion Imaging Reveals Two Spatially Separable Mechanisms In Mild TBI. *3rd Federal Interagency Conference on TBI*, Washington, DC, 2011.

- Shenton ME, *Pasternak O, *Bouix S, *Pelavin P, *Kubicki M, Zafonte R. Identification of Neuroinflammation in Mild Traumatic Brain Injury Using a Free Water Atlas, *9th World Congress on Brain Injury* (*IBIA*), Edinburgh, Scotland, March 22, 2012.

Our Publications, Proceedings, & Presentations

- Kaufmann D, *Koerte IK, *Muehlmann M, Hartl E, Reiser M, Makris N, *Rathi Y, Shenton ME, Ertl-Wagner B. White matter integrity of motor tracts in professional musicians and soccer players. Poster session. *European Society of Radiology (ESR)*, Vienna, Austria, 2013. A393.

- *Pasternak O, *Bouix S, *Rathi Y, Branch C, Westin C-F, Shenton M, Lipton M. Identification of mild traumatic brain injuries by comparison of free-water corrected z-distributions. *Proceeding of the 21st International Society for Magnetic Resonance in Medicine Meeting (ISMRM)*, Salt Lake City, UT (accepted; 2013).

- *Mayinger M, *Koerte IK, *Muehlmann M, Kaufmann D, *Purohit MP, Steffinger D, *Eckbo R, *Rathi Y, *Bouix S, *Pasternak O, Reiser M, Zafonte R, Stern RA, Ertl-Wagner B, *Kubicki M, Shenton ME. White matter integrity in professional soccer players without symptomatic concussion Poster presented at the 21st*Harvard Psychiatry Annual Research Day*, Sponsored by the Mysell Committee, Department of Psychiatry, Harvard Medical School, April 10, 2013.

- *Panenka WJ, Lange RT, Shewchuk JR, Heran MKS, Brubacher JR, *Bouix S, *Eckbo R, Shenton ME, Iverson GL. Biopsychosocial outcome from complicated versus uncomplicated mild traumatic brain injury. *International Brain Injury Association Tenth World Congress on Brain Injury (IBIA)*. March 2014. San Francisco, USA.

Our Publications, Proceedings, & Presentations

- *Pasternak O, *Bouix S, *Rathi Y, Branch C, Westin C-F, Shenton ME, Lipton M. Characterization of Acute Diffusion MRI Abnormalities following Concussion using a Joint Distribution Free-Water Imaging Normative Atlas. *International Brain Injury Association Tenth World Congress on Brain Injury (IBIA)*. March 2014. San Francisco, USA.

- *Pasternak O, Stern RA, *Giwerc MY, *Yergatian C, Merugumala S, Liao H, Baugh CM, Westin C-F, Shenton M**E**, *Lin AP. Identification of Atrophy, Excitotoxicity and Gliosis in the White Matter of Retired NFL Players. *International Brain Injury Association Tenth World Congress on Brain Injury (IBIA)*. March 2014. San Francisco, USA.

- *Koerte IK, *Mayinger M, *Green K, *Giwerc M, *Dahlben B, *Fredman E, *Eckbo R, Baugh CM, *Stamm J, Makris N, Lin AP, *Pasternak O, *Rathi Y, Stern RA, Shenton ME. White matter microstructure and cortical thickness in former NFL players. *International Brain Injury Association Tenth World Congress on Brain Injury (IBIA)*. March 2014. San Francisco, USA.

- *Bouix S, Cai P, *Pasternak O, Zafonte R, Shenton ME. Subject-Specific Evaluation of mTBI with Diffusion MRI: Statistical Considerations. *International Brain Injury Association Tenth World Congress on Brain Injury (IBIA)*. March 2014. San Francisco, USA.

Our Publications, Proceedings, & Presentations

- Shenton ME, *Koerte IK, *Bouix S, *Pasternak O, *Lin AP, *Mayinger M, *Coleman M, *Dahlben B, *Giwerc M, *Green K, *Stamm J, Helmer K, Zafonte R, Stern R. Invited Symposium on Chronic Traumatic Encephalopathy, "Advanced Neuroimaging in CE and Repetitive Concussive and Subconcussive Head Trauma". *International Brain Injury Association Tenth World Congress on Brain Injury (IBIA)*. March 2014. San Francisco, USA.

- *Pasternak O, Stern RA, *Giwerc M, *Yergatian C, Merugumala S, Liao H, Baugh CM, Westin C-F, Shenton ME, *Lin AP. The relation between free-water, atrophy and microstructural pathologies in NFL players – A combined diffusion MRI and MRS study. *International Society for Magnetic Resonance Imaging in Medicine (ISMRM*; May, 2014, Milan, Italy).

Talks

- Shenton ME: Invited Speaker, "Diagnostic and Prognostic Indicators of Traumatic Brain Injury." Exploring Diagnostic, Therapeutic, and Rehabilitative Strategies in NeuroHealth, TBI, and PTSD. *Center for Integration of Medicine and Innovative Technology* (CIMIT), Workshop, January 25, 2011.

- Shenton ME: Invited Speaker, "In-Process Review of Neuroimaging Techniques and Their Application to the Multi-Site Clinical Consortium on PTSD/TBI." Presented at the US Army Medical Research and Materiel Command, Combat Casualty Care Research Program In-Process Scientific Review, Department of the Army, January 31, 2011, Herndon, VA.

Our Publications, Proceedings, & Presentations

- *Bouix S: Oral presentation, Diagnosis of Diffuse Axonal Injury with Diffusion Tensor Imaging, *3rd Federal Interagency Conference on TBI*, Washington DC, 2011.

- *Pasternak O: Oral presentation, Diffusion Imaging Reveals Two Spatially Separable Mechanisms In Mild TBI. *3rd Federal Interagency Conference on TBI*, Washington, DC, 2011.

- Shenton ME: Invited Speaker, "Identification of Neuroinflammation in Mild Traumatic Brain Injury Using a Free Water Atlas, *9th World Congress on Brain Injury* (*IBIA*), Edinburgh, Scotland, March 22, 2012.

- Shenton ME: Speaker at the first Conference on Chronic Traumatic Encephalopathy sponsored by the Cleveland Clinic Lou Ruvo Center for Brain Health and Boston University, "Role of Neuroimaging in CTE Detection: MRI, MRS, and Emerging PET Tau Imaging", October 1, 2012, Las Vegas, Nevada.

- Shenton ME**:** Invited Speaker, "Advanced Imaging in Mild TBI" at the 93rd*New England Roentegen Ray Society*, January 11, 2013, Boston, MA.

- Shenton ME: Invited Speaker, "Utilizing Advanced Neuroimaging to Provide Insights into Mild Traumatic Brain Injury and Repetitive Brain Trauma: DTI, MRS, and Emerging Pet Tau Imaging." *The 3rd Annual Traumatic Brain Injury Conference*, March 7, 2013, Washington, DC.

Our Publications, Proceedings, & Presentations

- Shenton ME: Invited Speaker, “Advances in Neuroimaging and Their Application to Schizophrenia and Mild Traumatic Brain Injury”. Talk given to PGYII Residents in Psychiatry at the South Shore Residency Training Program in Psychiatry, Harvard Medical School. March 10, 2013.

- Shenton ME**:** Invited Talk, “Application of Neuroimaging to Understand Schizophrenia and Mild Traumatic Brain Injury”. Talk given to VISN Chief, Dr. Michael Mayo-Smith, March 13, 2013.

- Shenton ME: Invited Speaker, “Advanced Neuroimaging Techniques Applied to Schizophrenia, Mild Traumatic Brain Trauma, and Repetitive Brain Trauma”. Neuroscience and Brain Seminar Series, Children’s Hospital, Harvard Medical School, Boston, MA April 18, 2013.

- Shenton ME: Invited Speaker, “The Role of Neuroimaging in mTBI, Schizophrenia, and CTE: DTI, MRS, and Emerging PET Tau Imaging in CTE. BRAINMAP seminar series, Martinos Center, Charlestown Navy Yard, May 15, 2013.

- Shenton ME: Invited Speaker, “The role of advanced neuroimaging in mTBI and CTE: DTI, MRS, and Tau Imaging”. Special Lectures of Recent Psychiatry Neuroimaging, Department of Neuropsychiatry, Kansai Medical University, Hotel Agora Osaka, Japan, June 24, 2013.

Our Publications, Proceedings, & Presentations

- Shenton ME: Invited Speaker, "The Role of Advanced Neuroimaging in CTE: DTI, MRS, and Emerging PET Tau Imaging", Brain Trauma-Related Neurodegeneration Workshop, sponsored by the National Institute of Neurological Disorders and Stroke (NINDS), August 12, 2013.

- Shenton ME: Speaker, "Perspectives on Challenges of Reproducibility and Variability in Diffusion MRI," part of workgroup on "Developing Standards for Diffusion Magnetic Resonance Imaging, a Meeting of Experts", sponsored by the *Institute of Medicine* of *The National Academies*. August 22, 2013.

- Shenton ME: Invited talk, "MR and Diffusion Tensor Imaging in Schizophrenia and in Mild Traumatic Brain Injury," Bouve College of Health Sciences, Northeastern University, December 2, 2013. TBI Neuroimaging Interim Progress Report, *Congressionally Designated Medical Research Program (CDMRP)*, "Tau Imaging in Chronic Encephalopathy," Fort Detrick, Maryland, January 31, 2014.

- *Pasternak O: Invited talk, "Characterization of Acute Diffusion MRI Abnormalities following Concussion using a Joint Distribution Free-Water Imaging Normative Atlas." *International Brain Injury Association Tenth World Congress on Brain Injury (IBIA)*. March 2014. San Francisco, USA.

Our Publications, Proceedings, & Presentations

- *Pasternak O: Invited talk, "Identification of Atrophy, Excitotoxicity and Gliosis in the White Matter of Retired NFL Players." *International Brain Injury Association Tenth World Congress on Brain Injury (IBIA)*. March 2014. San Francisco, USA.

- *Koerte I: Invited talk, "White matter microstructure and cortical thickness in former NFL players." *International Brain Injury Association Tenth World Congress on Brain Injury (IBIA)*. March 2014. San Francisco, USA.

- Shenton ME: Chair (Co-Chair with Dr. Robert Stern), Symposium on Chronic Traumatic Encephalopathy, "Advanced Neuroimaging in CE and Repetitive Concussive and Subconcussive Head Trauma" *International Brain Injury Association Tenth World Congress on Brain Injury (IBIA)*. March 2014. San Francisco, USA.

- *Lin AP**:** Invited talk, "Regional Metabolite Profiles in Chronic Sports-Related Concussion. *International Brain Injury Association Tenth World Congress on Brain Injury (IBIA)*. March 2014. San Francisco, USA.

Other References of Interest

- Tysvaer AT, Storli OV, Bachen NI. Soccer injuries to the brain. A neurologic and electroencephalographic study of former players. *Acta Neurol Scand.* Aug 1989;80(2):151-156.
- Goldstein M. Traumatic brain injury: a silent epidemic (Editorial). *Ann Neurol* 1990; 27(3):327.
- Tysvaer AT, Lochen EA. Soccer injuries to the brain. A neuropsychologic study of former soccer players. *Am J Sports Med.* Jan-Feb 1991;19(1):56-60.
- Ruff RM, Camenzuli, L., Mueller, J. Miserable minority: emotional risk factors that influence the outcome of a mild TBI. *Brain Inj* 1996; 10(8):551-565.
- Jordan BD, Relkin NR, Ravdin LD, Jacobs AR, Bennett A, Gandy S. Apolipoprotein E epsilon4 associated with chronic traumatic brain injury in boxing. *JAMA.* Jul 9 1997;278(2):136-140.
- Ross BD, Ernst T, Kreis R, et al. 1H MRS in acute traumatic brain injury. *J Magn Reson Imaging.* Jul-Aug 1998;8(4):829-840.
- Matser JT, Kessels AG, Jordan BD, Lezak MD, Troost J. Chronic traumatic brain injury in professional soccer players. *Neurology.* Sep 1998;51(3):791-796.
- Matser EJ, Kessels AG, Lezak MD, Jordan BD, Troost J. Neuropsychological impairment in amateur soccer players. *JAMA.* Sep 8 1999;282(10):971-973.

Other References of Interest

- Riemann BL, Guskiewicz KM. Effects of mild head injury on postural stability as measured through clinical balance testing. *J Athl Train.* Jan 2000;35(1):19-25.

- Ashwal S, Holshouser BA, Shu SK, et al. Predictive value of proton magnetic resonance spectroscopy in pediatric closed head injury. *Pediatr Neurol.* Aug 2000;23(2):114-125.

- Kutner KC, Erlanger DM, Tsai J, Jordan B, Relkin NR. Lower cognitive performance of older football players possessing apolipoprotein E epsilon4. *Neurosurgery.* Sep 2000;47(3):651-657; discussion 657-658.

- Brooks WM, Friedman SD, Gasparovic C. Magnetic resonance spectroscopy in traumatic brain injury. *J Head Trauma Rehabil.* Apr 2001;16(2):149-164.

- Giza CC, Hovda DA. The Neurometabolic Cascade of Concussion. *J Athl Train.* Sep 2001;36(3):228-235.

- Beaulieu C. The basis of anisotropic water diffusion in the nervous system - a technical review. *NMR in biomedicine.* Nov-Dec 2002;15(7-8):435-455.

- Arfanakis K, Haughton VM, Carew JD, Rogers BP, Dempsey RJ, Meyerand ME. Diffusion tensor MR imaging in diffuse axonal injury. *AJNR Am J Neuroradiol* 2002; 23(5):794-802.

Other References of Interest

- Guskiewicz KM, Marshall SW, Bailes J, et al. Association between recurrent concussion and late-life cognitive impairment in retired professional football players. *Neurosurgery.* Oct 2005;57(4):719-726; discussion 719-726.

- Serbest G, Burkhardt MF, Siman R, Raghupathi R, Saatman KE. Temporal profiles of cytoskeletal protein loss following traumatic axonal injury in mice. *Neurochem Res.* Dec 2007;32(12):2006-2014.

- Guskiewicz KM, Marshall SW, Bailes J, et al. Recurrent concussion and risk of depression in retired professional football players. *Med Sci Sports Exerc.* Jun 2007;39(6):903-909.

- Bazarian JJ, Zhong J, Blyth B, Zhu T, Kavcic V, Peterson D. DTI detects clinically important axonal damage after mild TBI: a pilot study. *J Neurotrauma* 2007; 24(9):1447-1459.

- Wilde EA, McCauley SR, Hunter JV, et al. Diffusion tensor imaging of acute mild traumatic brain injury in adolescents. *Neurology.* Mar 18 2008;70(12):948-955.

- Niogi SN, Mukherjee P, Ghajar J, et al. Extent of microstructural white matter injury in postconcussive syndrome correlates with impaired cognitive reaction time: a 3T diffusion tensor imaging study of mild traumatic brain injury. *AJNR Am J Neuroradiol.* May 2008;29(5):967-973.

Other References of Interest

- Lipton ML, Gellella E, Lo C, et al. Multifocal white matter ultrastructural abnormalities in mild traumatic brain injury with cognitive disability: a voxel-wise analysis of diffusion tensor imaging. *J Neurotrauma.* Nov 2008;25(11):1335-1342.

- Hoge CW, McGurk D, Thomas JL, Cox AL, Engel CC, Castro CA. Mild TBI in U.S. Soldiers returning from Iraq. *N Engl J Med* 2008; 358(5):453-463.

- Niogi SN, Mukherjee P, Ghajar J, et al. Structural dissociation of attentional control and memory in adults with and without mild traumatic brain injury. *Brain.* Dec 2008;131(Pt 12):3209-3221.

- McKee AC, Cantu RC, Nowinski CJ, et al. Chronic traumatic encephalopathy in athletes: progressive tauopathy after repetitive head injury. *J Neuropathol Exp Neurol.* Jul 2009;68(7):709-735.

- Lipton ML, Gulko E, Zimmerman ME, et al. Diffusion-tensor imaging implicates prefrontal axonal injury in executive function impairment following very mild traumatic brain injury. *Radiology.* Sep 2009;252(3):816-824.

- Niogi SN, Mukherjee P. Diffusion tensor imaging of mild traumatic brain injury. *J Head Trauma Rehabil.* Jul-Aug 2010;25(4):241-255.

Other References of Interest

- Wu TC, Wilde EA, Bigler ED, et al. Longitudinal changes in the corpus callosum following pediatric traumatic brain injury. *Dev Neurosci.* 2010;32(5-6):361-373.

- Messe A, Caplain S, Paradot G, et al. Diffusion tensor imaging and white matter lesions at the subacute stage in mild traumatic brain injury with persistent neurobehavioral impairment. *Hum Brain Mapp.* Jun 2011;32(6):999-1011.

- Mac Donald CL, Johnson AM, Cooper D, Nelson EC, Werner NJ, Shimony JS, Snyder AZ, Raichle ME, Witherow JR, Fang R, Flaherty SF, Brody DL. Detection of blast-related traumatic brain injury in U.S. military personnel. *N Engl J Med* 2011; 364(22):2091-2100.

- Budde MD, Janes L, Gold E, Turtzo LC, Frank JA. The contribution of gliosis to diffusion tensor anisotropy and tractography following traumatic brain injury: validation in the rat using Fourier analysis of stained tissue sections. *Brain.* Aug 2011;134(Pt 8):2248-2260.

- Stern RA, Riley DO, Daneshvar DH, Nowinski CJ, Cantu RC, McKee AC. Long-term consequences of repetitive brain trauma: chronic traumatic encephalopathy. *PM R.* Oct 2011;3(10 Suppl 2):S460-467.

- Arenivas A, Diaz-Arrastia R, Spence J, et al. Three approaches to investigating functional compromise to the default mode network after traumatic axonal injury. *Brain Imaging Behav.* Jul 31 2012.

Other References of Interest

- Goldstein LE, Fisher AM, Tagge CA, Zhang XL, Velisek L, Sullivan JA, Upreti C, Kracht JM, Ericsson M, Wojnarowicz MW, Goletiani CJ, Maglakelidze GM, Casey N, Moncaster JA, Minaeva O, Moir RD, Nowinski CJ, Stern RA, Cantu RC, Geiling J, Blusztajn JK, Wolozin BL, Ikezu T, Stein TD, Budson AE, Kowall NW, Chargin D, Sharon A, Saman S, Hall GF, Moss WC, Cleveland RO, Tanzi RE, Stanton PK, McKee AC. Chronic traumatic encephalopathy in blast-exposed military veterans and a blast neurotrauma mouse model. *Sci Transl Med* 2012; 4(134):134ra60.

- Wilde EA, Ayoub KW, Bigler ED, Chu ZD, Hunter JV, Wu TC, McCauley SR, Levin HS. Diffusion tensor imaging in moderate-to-severe pediatric traumatic brain injury: changes within an 18 month post-injury interval. *Brain Imaging Behav* 2012; 6(3):404-16.

- Defense and Veterans Brain Injury Center, 2012, at www.dvbic.org/dod-worldwide-numbers-tbi.

- Tremblay S, De Beaumont L, Henry LC, et al. Sports concussions and aging: a neuroimaging investigation. *Cereb Cortex.* May 2013;23(5):1159-1166.

- Zhou Y, Kierans A, Kenul D, et al. Mild traumatic brain injury: longitudinal regional brain volume changes. *Radiology.* Jun 2013;267(3):880-890.

- Lipton ML, Kim N, Zimmerman ME, et al. Soccer Heading Is Associated with White Matter Microstructural and Cognitive Abnormalities. *Radiology.* Jun 11 2013.

Other References of Interest

- Ozarslan E, Koay CG, Shepherd TM, et al. Mean apparent propagator (MAP) MRI: a novel diffusion imaging method for mapping tissue microstructure. *Neuroimage.* Sep 2013;78:16-32.

- Clay MB, Glover KL, Lowe DT. Epidemiology of concussion in sport: a literature review. *Journal of chiropractic medicine.* Dec 2013;12(4):230-251.

- Bigler ED. Neuroinflammation and the dynamic lesion in traumatic brain injury. *Brain* 2013; 136(Pt 1):9-11.

- Levin HS, Robertson CS. Mild traumatic brain injury in translation. *J Neurotrauma* 2013; 30(8):610-617.

- Mac Donald C, Johnson A, Cooper D, Malone T, Sorrell J, Shimony J, Parsons M, Snyder A, Raichle M, Fang R, Flaherty S, Russell M, Brody DL. Cerebellar white matter abnormalities following primary blast injury in US military personnel. *PLoS One* 2013; 8(2):e55823.

- Luo J, Nguyen A, Villeda S, et al. Long-term cognitive impairments and pathological alterations in a mouse model of repetitive mild traumatic brain injury. *Frontiers in neurology.* 2014;5:12.