Cerebellar Injury in Mild TBI: Clinical Implications

Elaine R. Peskind, MD

Co-Director

VISN 20 Mental Illness Research, Education, and Clinical Center (MIRECC)

Friends of Alzheimer's Research Professor

Department of Psychiatry & Behavioral Sciences
University of Washington School of Medicine

Staff Psychiatrist, Joint Base Lewis-McChord, Tacoma WA

The Nature of an Emerging and Unprecedented Problem

Helmand Province, Afghanistan, July 13, 2009 (MSNBC)

2.6 million Service Members have been deployed to Iraq and Afghanistan; approximately 9-18% return with symptomatic mTBI.

Los Angeles Times

Junior Seau had degenerative brain disease when he committed suicide



28 year old U.S Marine Veteran

- 2 combat deployments: multiple blast concussions, combat PTSD
- 3 non-military impact mTBIs
  - sports-related prior to and post-deployment: ages 12, 17, 26
- Behavioral and cognitive symptoms:
  - Persistent anxiety, exacerbation of PTSD, difficulty concentrating, word-finding difficulties, learning and memory impairment, reduced psychomotor speed
- Death by suicide from self-inflicted gunshot age 28

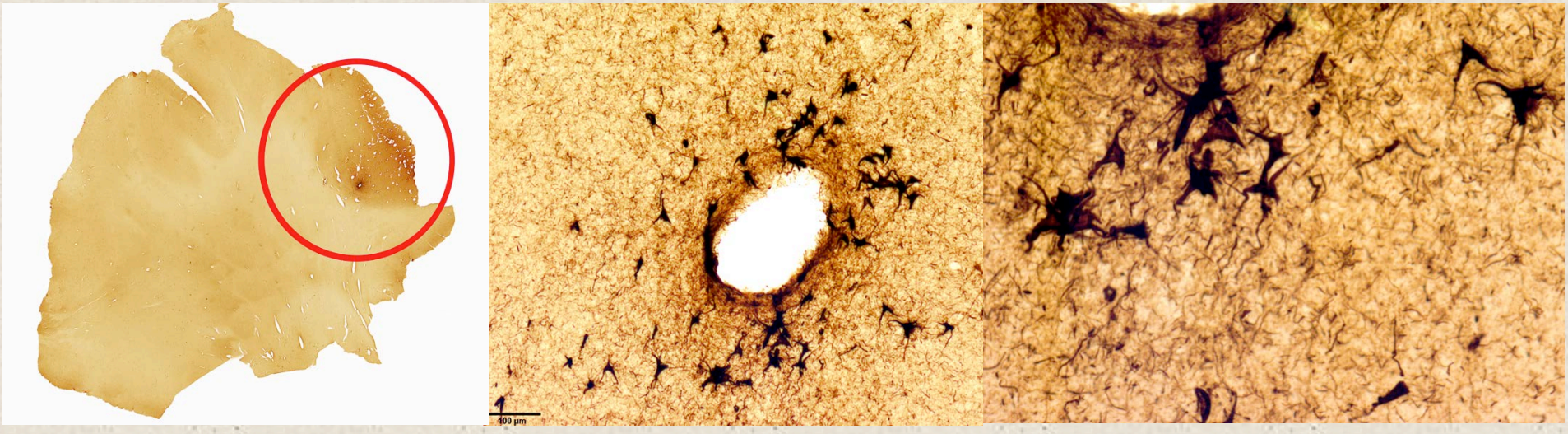

Stage I CTE

Concussive and Subconcussive Head Injury and Risk of Neurodegeneration

- Repetitive sports concussion is associated with increased risk of the **rare** mid-life dementing disorder (in the general population), chronic traumatic encephalopathy (CTE)

- Traumatic brain injury (TBI) is currently the best characterized environmental risk factor for developing the **common** late-life dementing disorder, Alzheimer's disease

Participants to Date

- 54 male Iraq/Afghanistan Veterans with blast-induced mild traumatic brain injury
  - 70% have comorbid combat trauma PTSD
  - Higher rates of depression, alcohol use, and poorer sleep
  - Nearly all have persistent postconcussive symptoms
- 25 non blast-exposed Iraq/Afghanistan Veterans

Neurobehavioral Symptom Inventory Item Frequency (%) Rated Moderate Severe, or Very Severe in 34 Iraq/Afghanistan Veterans with mTBI and 16 Deployed Controls with No Blast Exposure

	TBI (N=33)	Control (N=15)	p*
Forgetfulness	67 %	20 %	.001
Feeling anxious or tense	67 %	13 %	<.0001
Difficulty falling or staying asleep	64 %	13 %	.002
Ringing in ears	64 %	0	<.0001
Irritability	61 %	13 %	<.0001
Headaches	61 %	7 %	<.0001
Sensitivity to noise	58 %	0	<.0001
Poor concentration/attention	52 %	13 %	.001
Hearing difficulty	52 %	0	<.0001
Slowed thinking	52 %	13 %	.001

Blast Exposure History

- Average time since last blast exposure was **4 years**
- Average of only one blast exposure resulting in loss of consciousness – most mTBIs with **alteration** of consciousness
- Majority had **repetitive** mTBI:
  - Average number of blast exposures in Iraq or Afghanistan in the mTBI group was **20**
  - More common to have **50-100** blast exposures than a single blast exposure

Dose-dependent Relationship Between Number of Blast mTBIs and Neurobehavioral Symptom Inventory Clusters

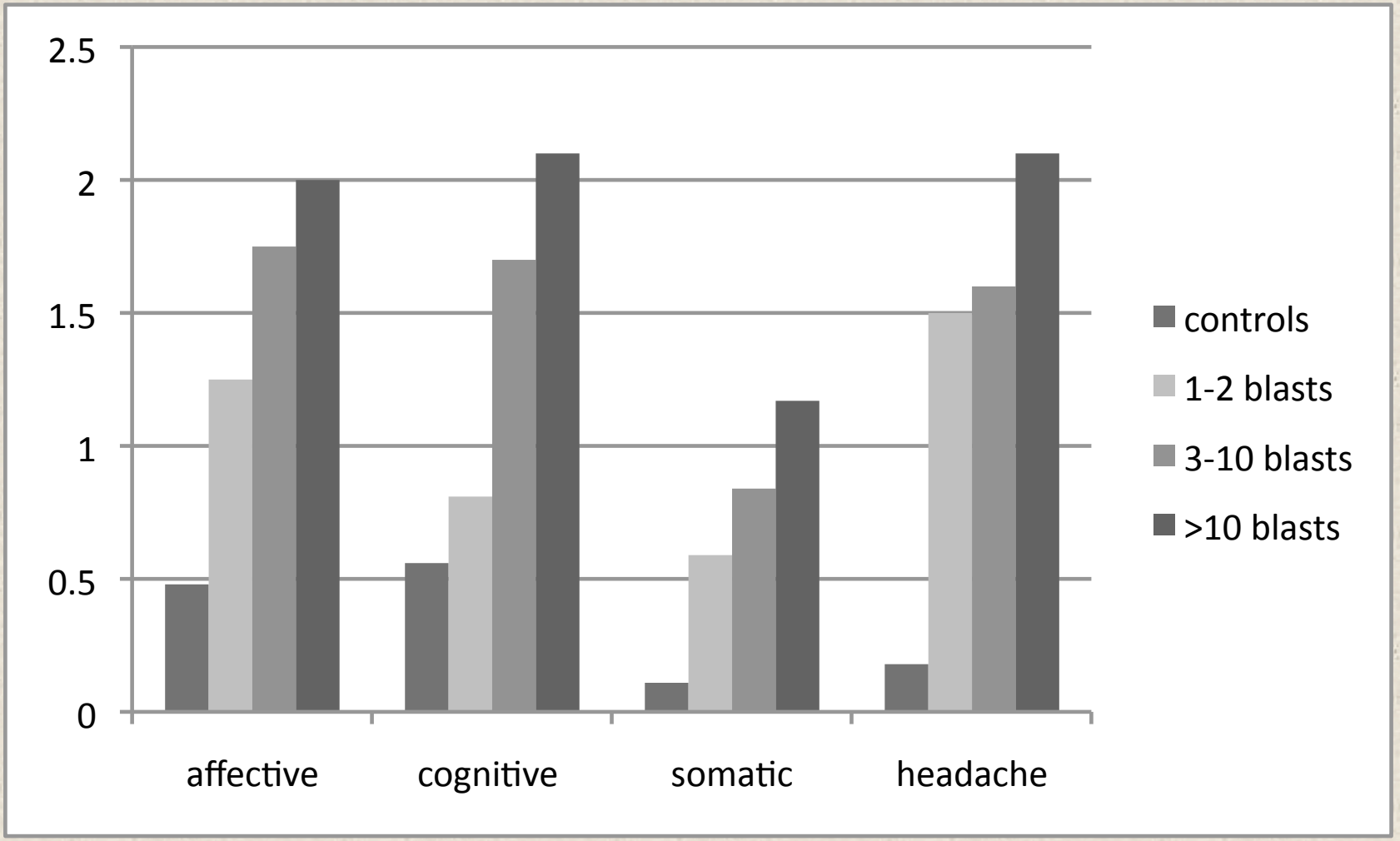

Neuropsychological Assessment: Results

- Veterans with a history of repeated blast-related mTBI demonstrate a range of intact cognitive abilities, with subtle cognitive difficulties measurable in the domains of:
  - **processing speed**
  - **prospective memory** on Memory for Intentions Test (MIST)
- Objective results are consistent with Veterans' subjective self reports of **everyday cognitive challenges**

Multimodal Neuroimaging

- Structural Neuroimaging
  - Diffusion Tensor Imaging
  - Macromolecular Proton Fraction (MPF) Mapping
- Functional Neuroimaging:
  - Resting state functional MRI (fcMRI)
  - Task-based fcMRI using N-Back Task
  - [^{18}F]-Fluorodeoxyglucose Positron Emission Tomography ([^{18}F]-FDG-PET)

Diffusion Tensor Imaging: Results

- Preliminary results from our laboratory show decreased FA in corpus callosum an average of **4 years** following last blast exposure in Iraq and Afghanistan Veterans with mTBI vs. deployed control Veterans without TBI, consistent with diffuse axonal injury.
- These results could **not** be attributed to PTSD.
- DTI studies in Iraq/Afghanistan Veterans vary among labs – both in Methods and Results
- Are there other structural MRI techniques which may be **more sensitive** to chronic changes following blast concussion mTBI?

Macromolecular Proton Fraction (MPF) Mapping

- MPF is a magnetization transfer structural imaging technique which provides an index of macromolecular composition.
- MPF correlates with indices of central **myelin integrity** in humans and in animal models of multiple sclerosis and spinal cord injury.

Magnetization Transfer Molecular Proton Bound Fraction (MPF): Z-score subtraction maps of MPF values in Blast-mTBI Veterans (N=27) compared to Nonblast Veterans (N=16)

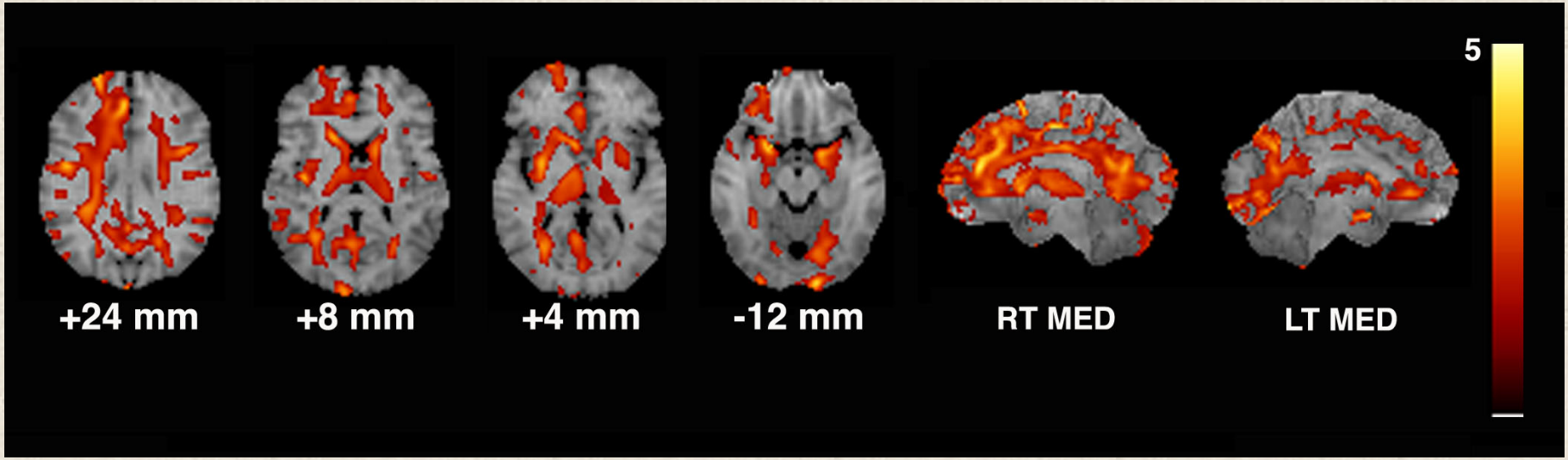

- **RESULTS**:
- Reduced MPF in **numerous** subgyral, cortical-subcortical, and longitudinal white matter (WM) tracts (Zs>4.0, all p's <0.05)
- Within mTBI group**, no differences** between Veterans with and without PTSD

Petrie et al, *Journal of Neurotrauma* 31:425-436, 2013

Macromolecular Proton Bound Fraction (f): Voxelwise Subtraction Analysis Results

Structure*	Tissue Component	Coordinates (mm)¶	Z score	Reduction (%)@
R External Capsule	WM	(-30, -1, 0)	4.4	10.5 ‡
R Internal Capsule, Anterior Limb	WM	(-17, 17, 9)	4.0	12.3 §
R Superior Longitudinal Fasciculus	WM	(-44, -6, 27)	4.1	16.3 ‡
R Superior Frontal Gyrus	GM	(-24, 59, 22)	4.6	35.8 §
	WM	(-17, -13, 45)	4.4	7.2 §
	GM/WM Border	(-17, 8, 58)	4.0	27.0 §
	GM/WM Border	(-6, 32, 27)	4.0	17.6 ‡
	GM	(-24, 66, 7)	4.0	36.4 ‡
R Middle Frontal Gyrus	WM	(-39, 1, 47)	4.4	19.6 ‡
	GM	(-46, 50, -2)	4.1	28.1 †
	GM/WM Border	(-37, 48, -4)	4.3	16.7 ‡
L Inferior Frontal Gyrus	GM/WM Border	(42, 5, 20)	4.3	24.3 §
R Medial Orbital Gyrus	GM	(-26, 37, -16)	4.2	30.5 ‡
	GM	(-21, 5, -11)	4.1	18.4 ‡
R Precentral Gyrus	WM	(-19, -17, 45)	4.4	8.1 §
	GM	(-46, -13, 43)	4.1	19.6 ‡
R Anterior Cingulate Gyrus	GM	(-3, 41, 18)	4.5	23.6 §
L Subcallosal Gyrus	GM	(15, 3, -14)	4.3	32.5 §
L Superior Parietal Lobule	WM	(15, -62, 32)	4.0	15.6 §
R Precuneus	WM	(-21, -58, 38)	4.2	16.8 §
L Lingual Gyrus	GM	(12, -91, -11)	4.2	20.2 §

† $p<0.05$, ‡ $p<0.01$, § $p<0.001$ (Independent groups t-test, one-tailed)

Petrie et al, *Journal of Neurotrauma* 31:425-436, 2013

Conclusions - MPF

- Observed reduction of bound pool fraction in white matter is consistent with **diffuse axonal injury.**
- Voxelwise analysis of MPF images demonstrate decreased myelin density suggestive of **myelin structural damage.**
- Altered MPF parameters have **potential** as prospective quantitative biomarkers of blast-induced mTBI.

The number of blast exposures correlates significantly with resting state global normalized FDG-PET hypometabolism—with prominent associations in the posterior cerebellum

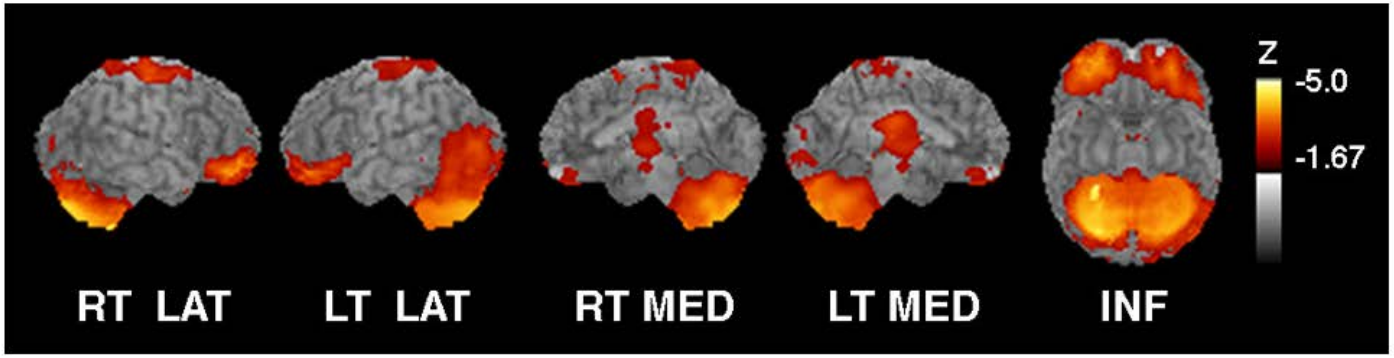

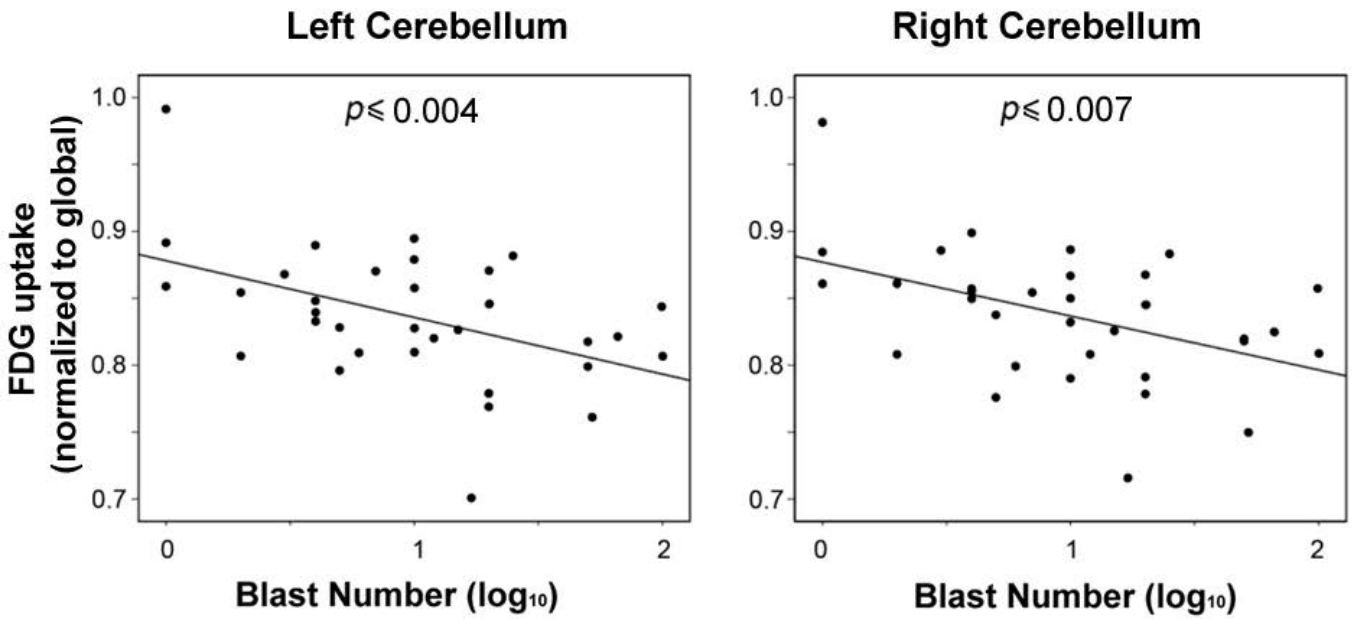

Meabon et al, *Science Translational Medicine* 8:1-15, 2016

Shock Tube



Mild shock tube-induced blast wave replicates open-field blast waveform expected from 16 kg of TNT detonated at a 7.6 m standoff

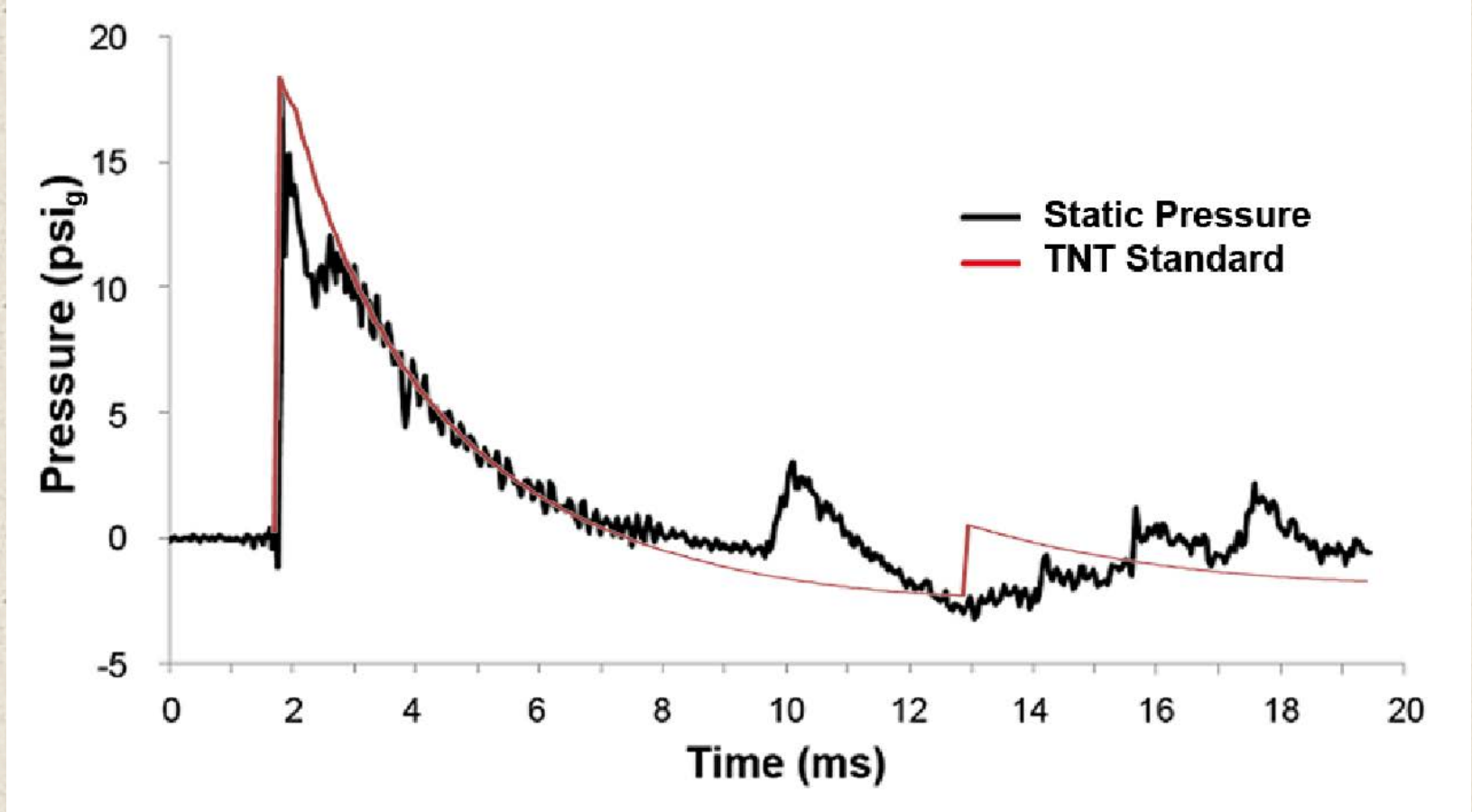

A single mild blast produces focal patches of pathology in cerebellum prevalently localized in the posterior lobules overlaying the 4th ventricle

Sham

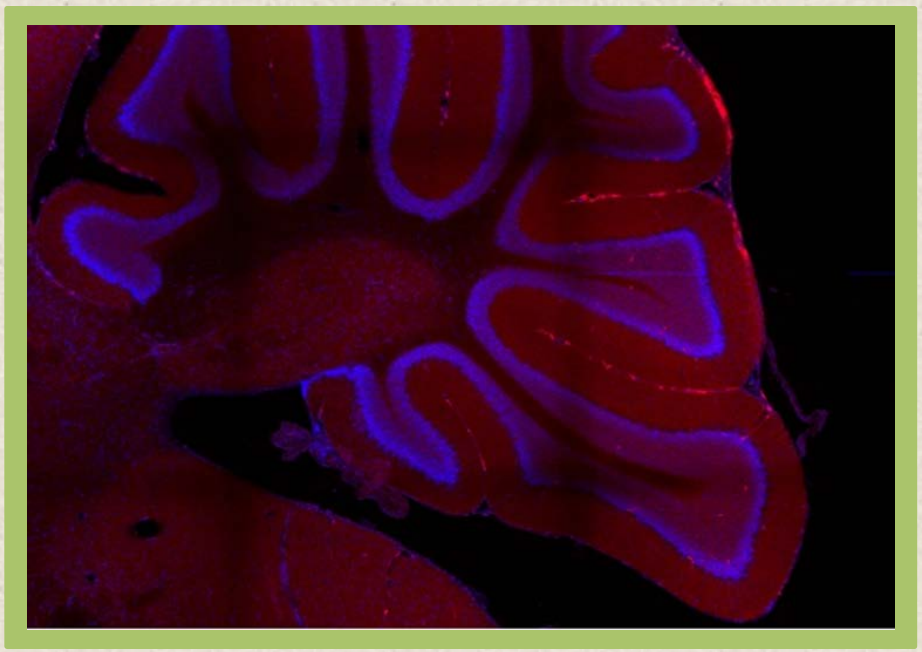

Blast

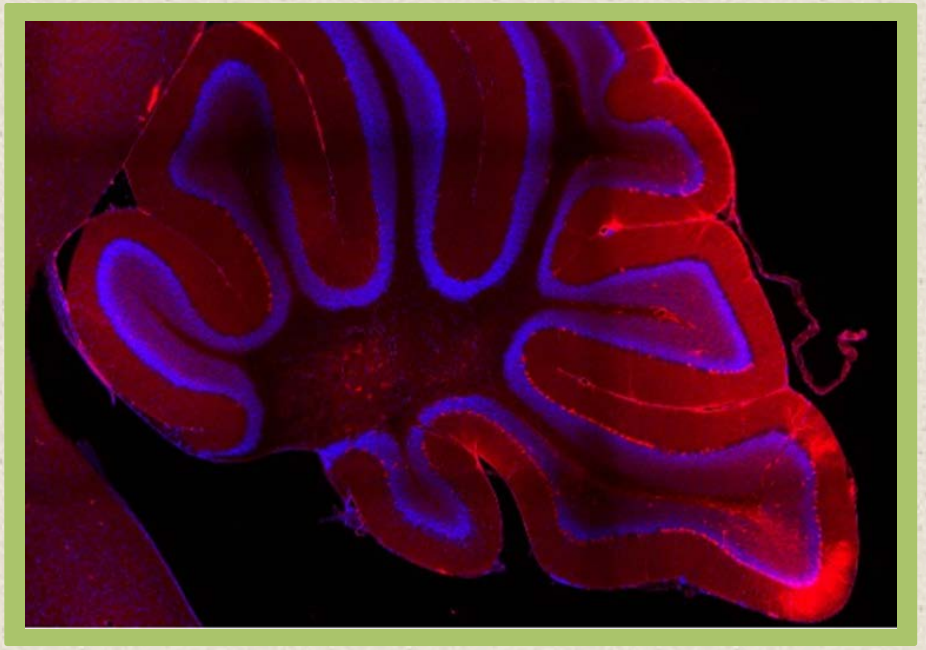

Red: Dextran
Blue: Dapi

Meabon et al, *Science Translational Medicine* 8:1-15, 2016

Mild blast induces Purkinje cell pathology

Sham **Blast**

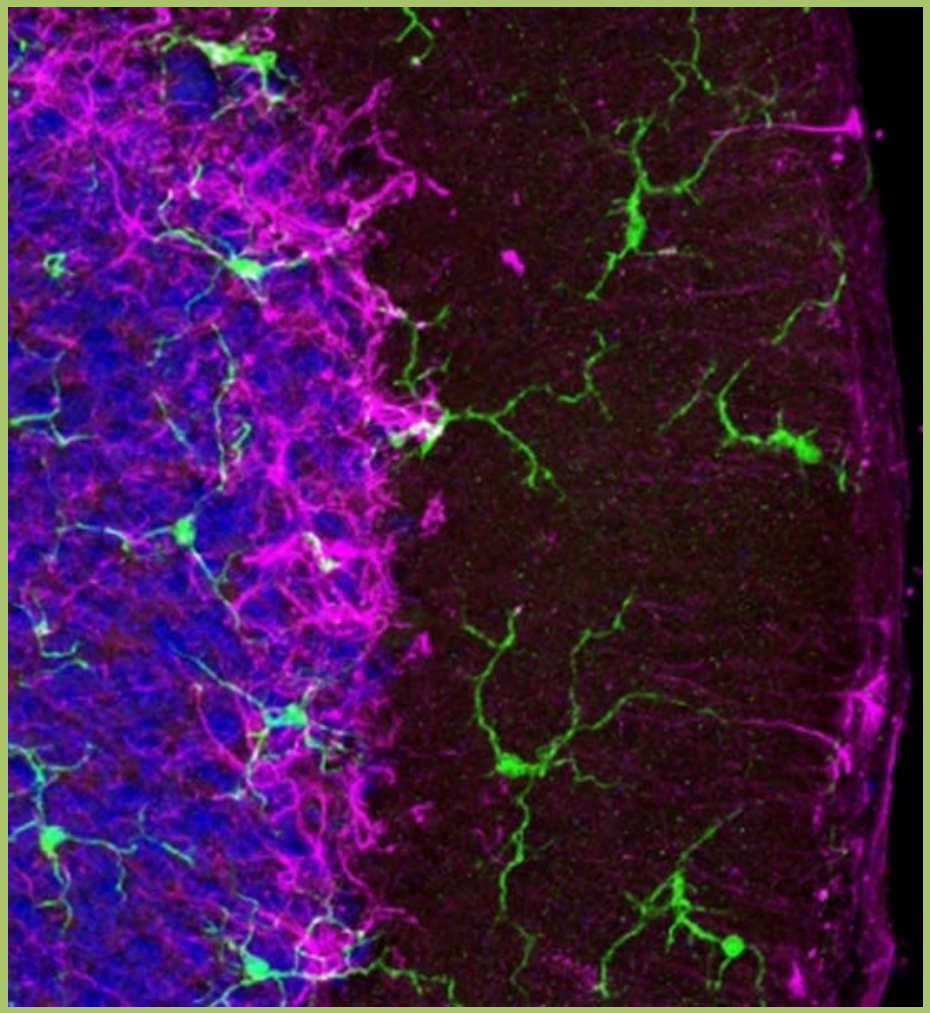

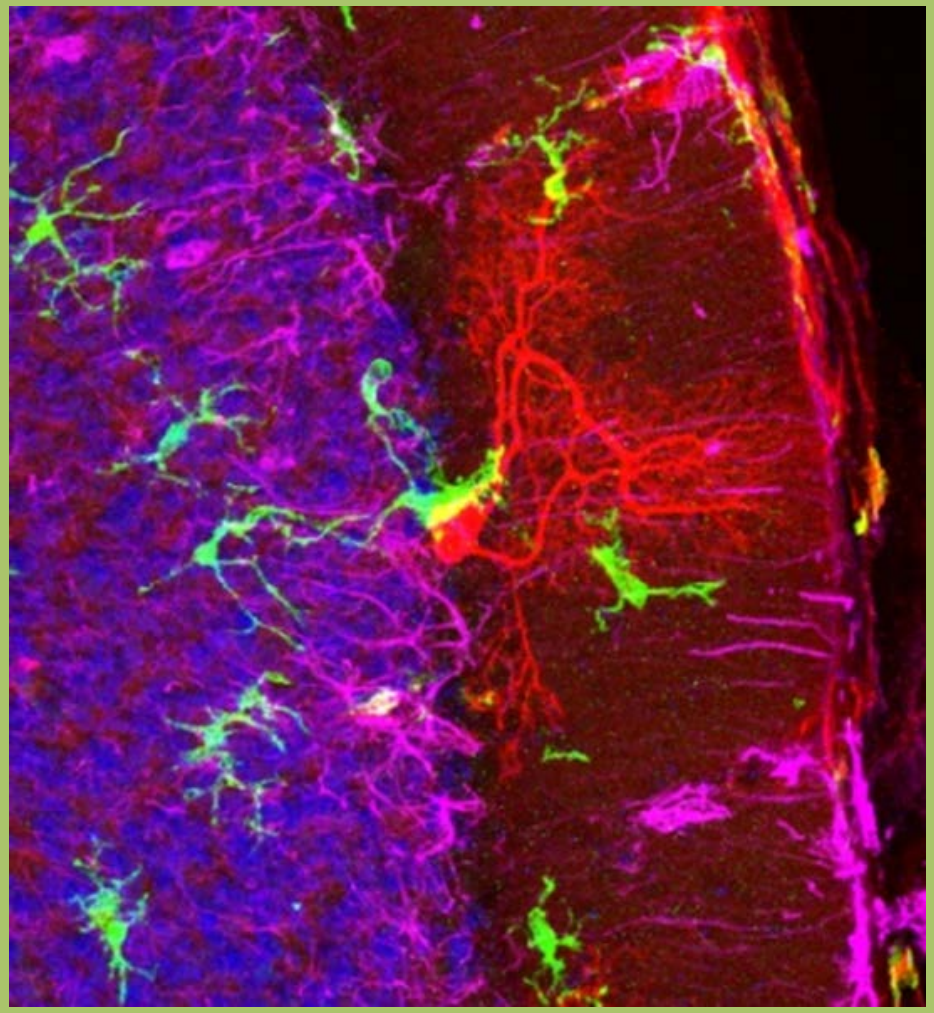

Meabon et al, *Science Translational Medicine* 8:1-15, 2016

Green: Iba1 Pink: GFAP
Red: Dextran Blue: Dapi

Repetitive blast exposure induces progressive loss of cerebellar Purkinje cells

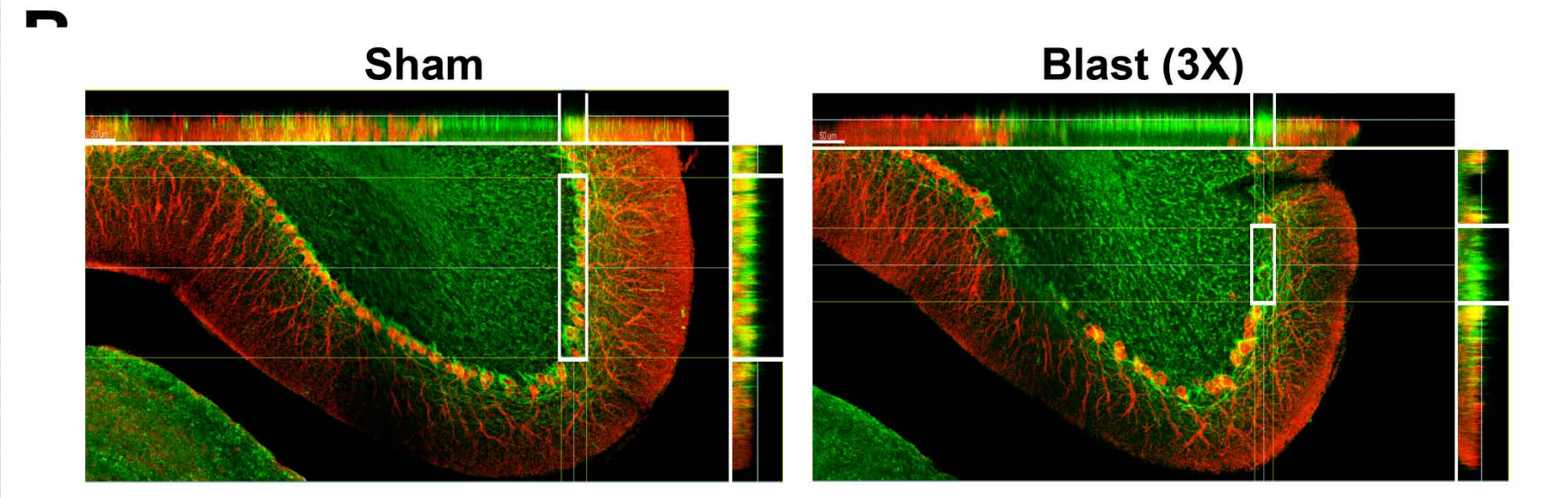

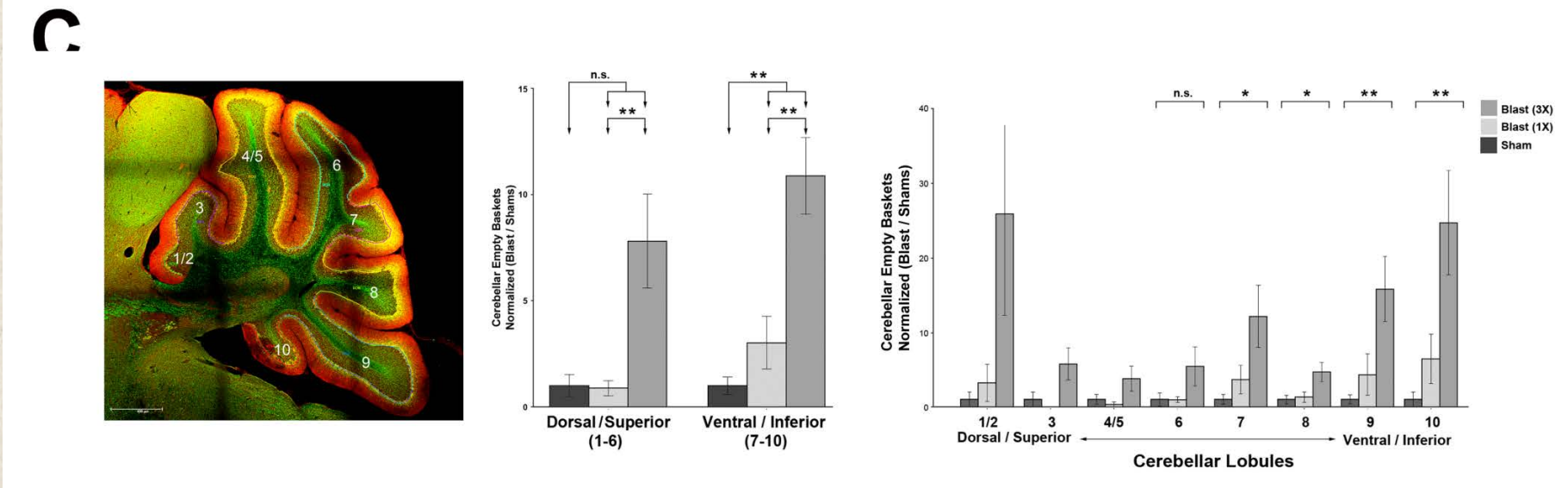

Meabon et al, *Science Translational Medicine* 8:1-15, 2016

Blast-induced mTBI pathology in mouse cerebellum appears very similar to repetitive sports-related TBI in cerebellum

Psychological Medicine, 1973, 3, 270-303

The aftermath of boxing[1]

J. A. N. CORSELLIS, C. J. BRUTON, AND DOROTHY FREEMAN-BROWNE[2]

From the Department of Neuropathology, Runwell Hospital, Wickford, Essex

SYNOPSIS The brains of 15 retired boxers have been studied and the lives of the men concerned have been investigated in retrospect. A characteristic pattern of cerebral change has been identified which appears not only to be a result of the boxing but also to underlie many features of the punch-drunk syndrome.

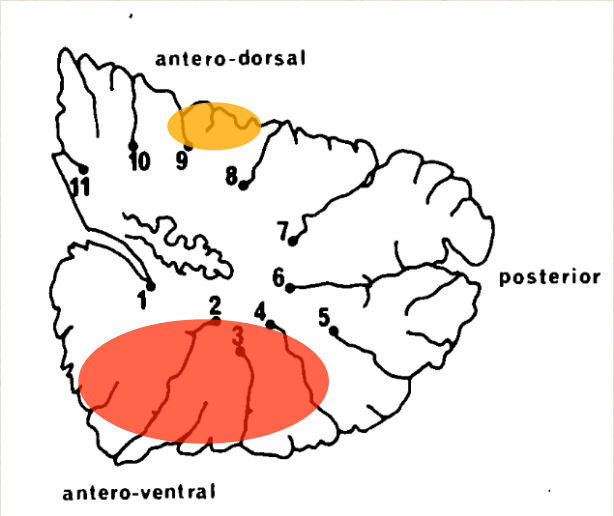

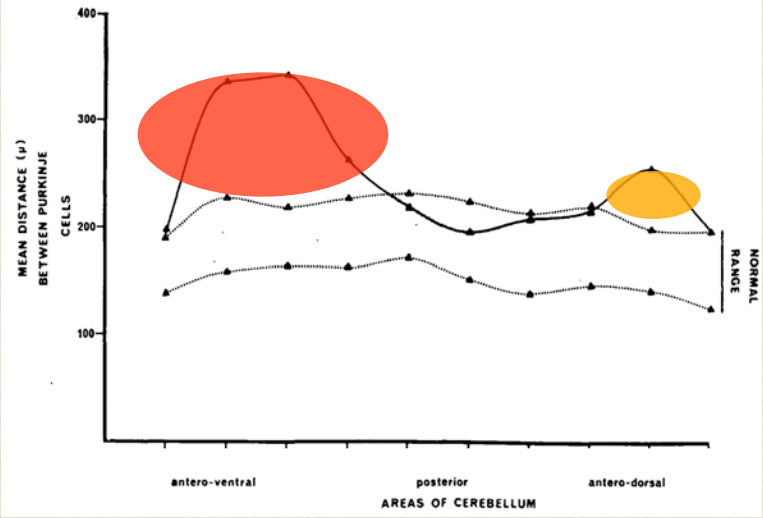

Multiple mild blasts induce prolonged sensorimotor impairment in blast exposed mice

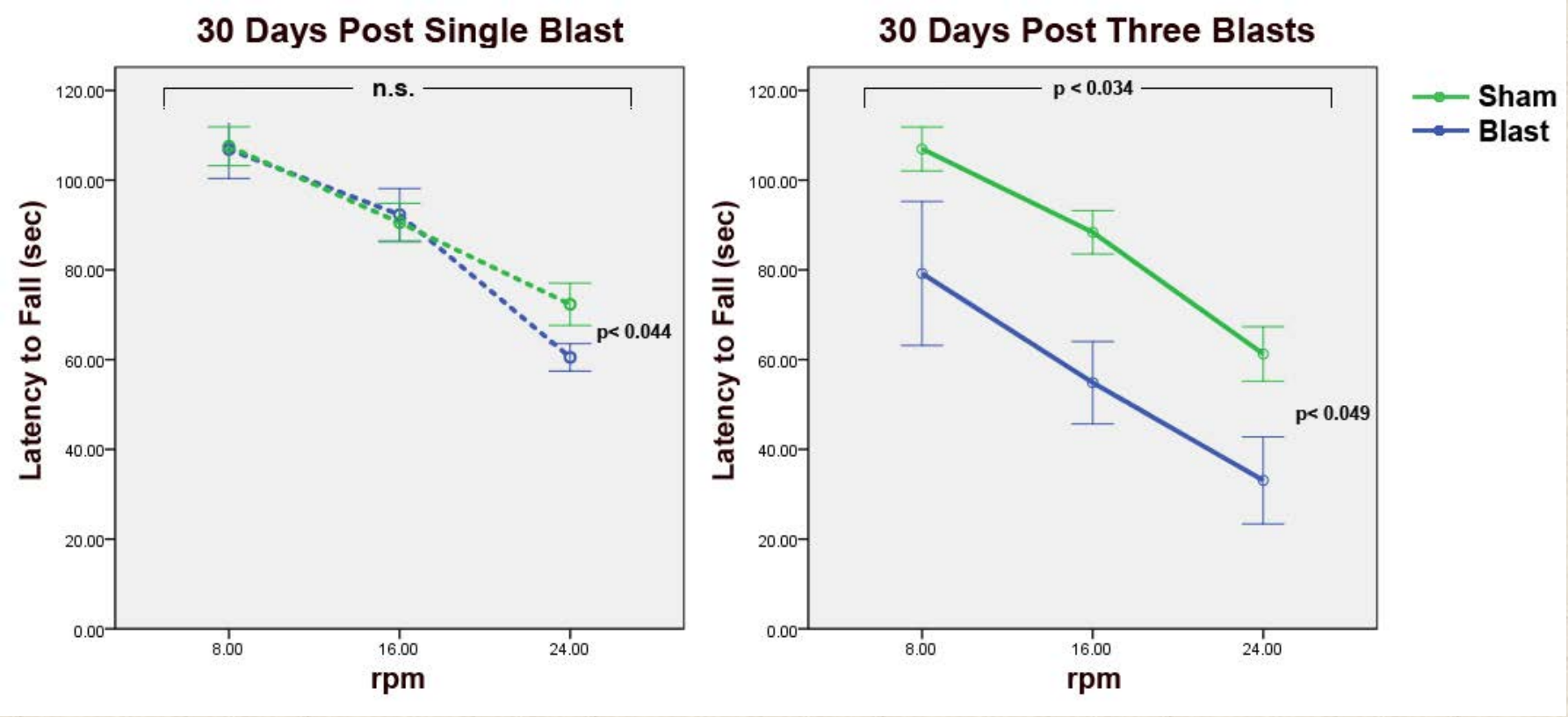

Meabon et al, *Science Translational Medicine* 8:1-15, 2016

Sensorimotor symptoms in blast-exposed Veterans correlate with number of blast-related mTBIs

Correlation between number (log_{10}) of blast-related mTBIs and symptoms related to sensorimotor integration (N=41)		
Symptom	**Spearman r**	***p*-value**
Dizziness	0.374	0.016
Loss of Balance	0.431	0.005
Poor Coordination	0.365	0.019
Total (D+LB+PC)	0.438	0.004

Neurobehavioral Symptom Inventory (NSI). Symptoms rated by participants as none to severe (0-4).

Meabon et al, *Science Translational Medicine* 8:1-15, 2016

Task-based functional MRI in blast-exposed Veterans

As N-back task becomes more difficult:

- **Working Memory Network is increasingly activated (frontal cortex, parietal cortex, Cerebellum)**
- **Default Mode Network is suppressed as WMN is activated (mPFC, posterior cingulate and aspects of parietal cortex)**

Task-based functional MRI in a blast-exposed Veterans: N-back Task reveals altered activation in cerebellum and medial prefrontal cortex (mPFC)

In blast-exposed Veterans: cerebellum is less activated

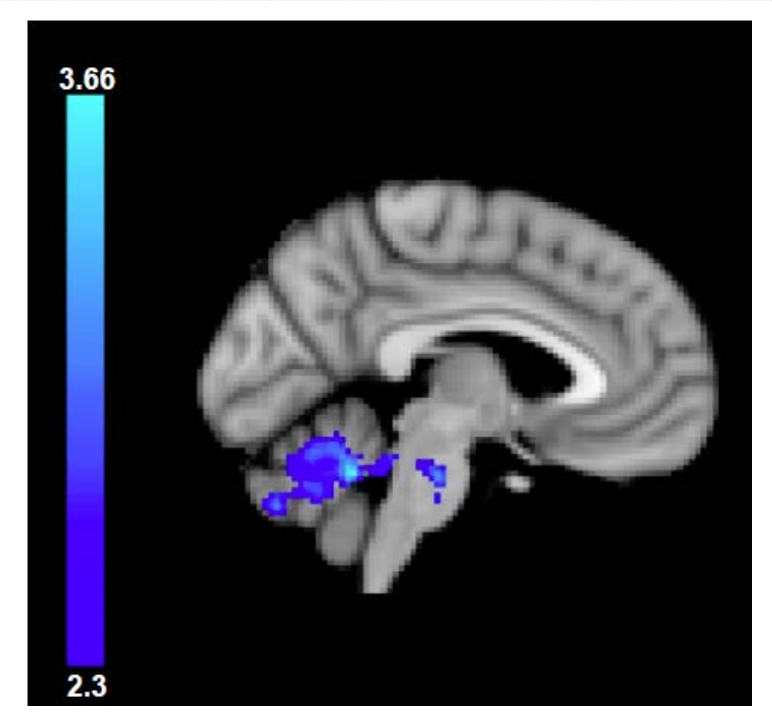

Controls > mTBI

In blast-exposed Veterans: failure to suppress mPFC

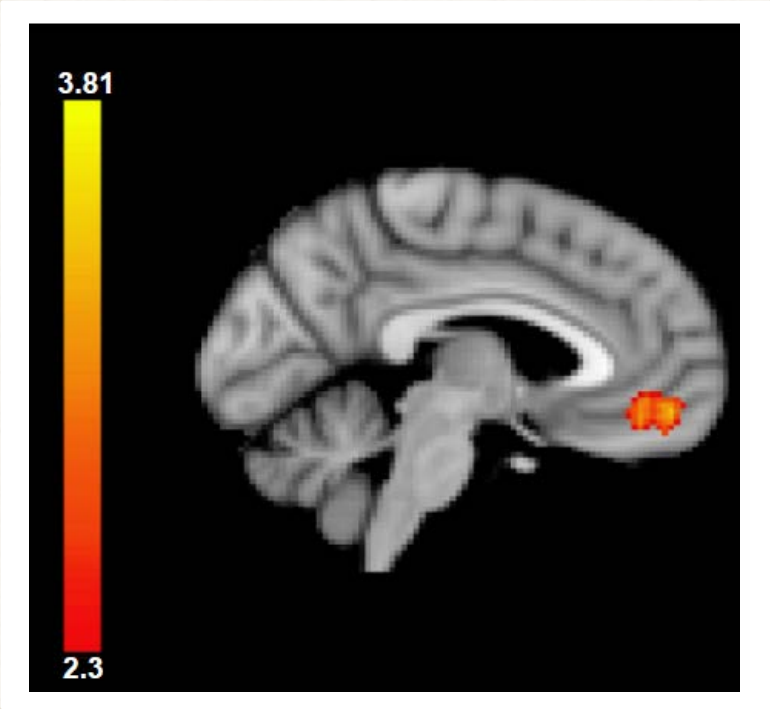

mTBI > Controls

Data from Kathleen Pagulayan, PhD, MIRECC, Seattle VA

In Veterans, increasing number of blast-related mTBIs correlates significantly with decreased Mean Diffusivity in white matter tracts of the deep cerebellum/cerebellar peduncle

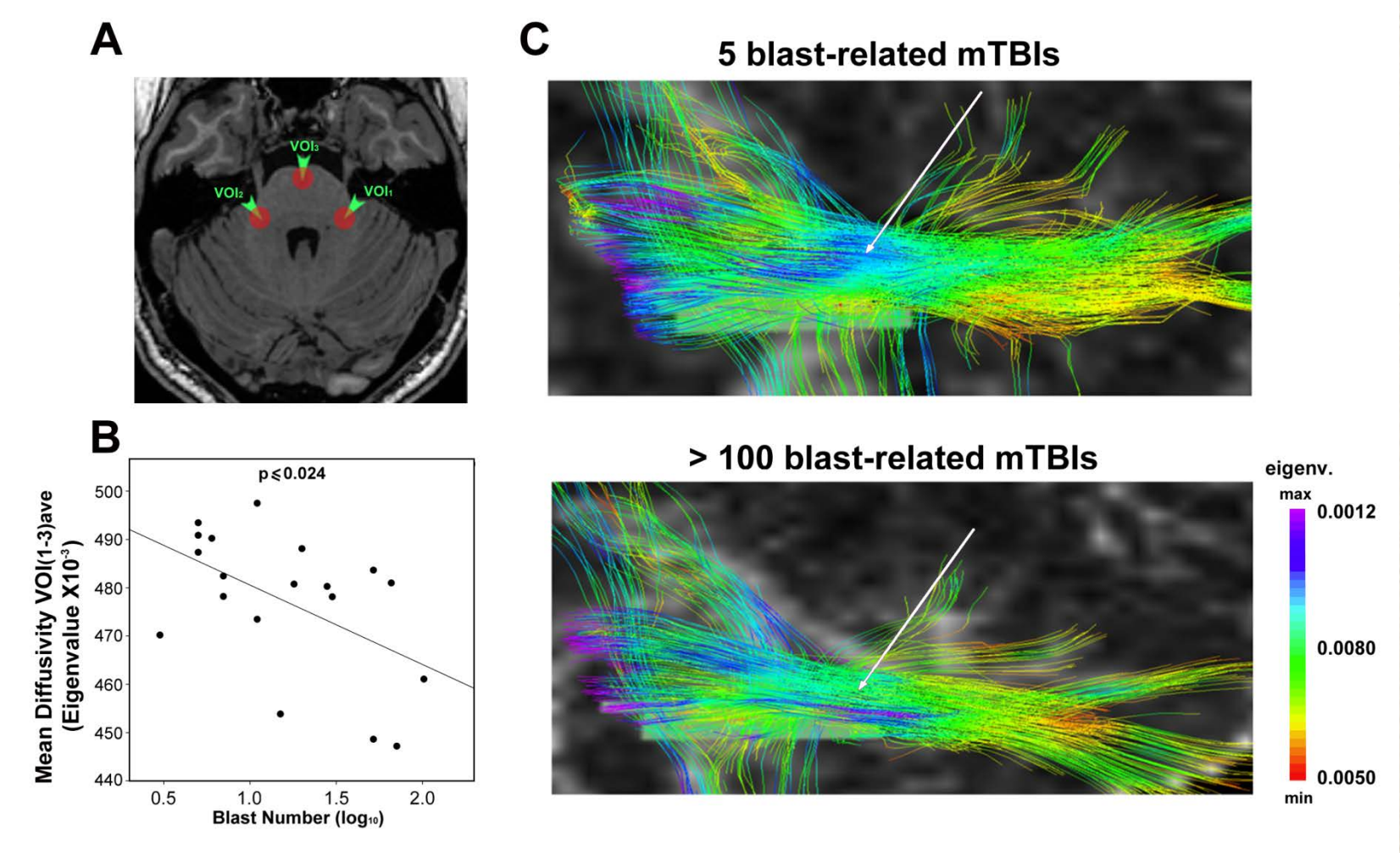

Meabon et al, Science Translational Medicine 8:1-15, 2016

In addition to sensorimotor integration the cerebellum plays important concurrent roles in an array of cognitive and emotional functions

Cerebellum (2014) 13:151–177

Consensus Paper: The Cerebellum's Role in Movement and Cognition

Leonard F. Koziol · Deborah Budding · Nancy Andreasen · Stefano D'Arrigo · Sara Bulgheroni · Hiroshi Imamizu · Masao Ito · Mario Manto · Cherie Marvel · Krystal Parker · Giovanni Pezzulo · Narender Ramnani · Daria Riva · Jeremy Schmahmann · Larry Vandervert · Tadashi Yamazaki

Cognitive/behavioral symptoms in patients with cerebellar disorders

Attentional control
- Inattentiveness
- Distractibility
- Hyperactivity
- Compulsive behaviors

Emotional control
- Impulsiveness
- Lability and unpredictability
- Anxiety, agitation, panic

Autism spectrum
- Stereotypical behaviors
- Self-stimulation behaviors

Psychotic disorders
- Illogical thought
- Paranoia
- Hallucinations

Social skill set
- Anger and aggression
- Irritability
- Overly territorial
- Oppositional behavior

Summary and Conclusions

- Graded **structural and functional imaging abnormalities** suggest a coherent picture of **diffuse axonal injury** in Iraq/ Afghanistan Veterans with blast concussion mTBI specific to TBI and not attributable to PTSD.
- mTBI Veterans have **neurocognitive deficits** which correspond to their **real-life complaints** of cognitive difficulties.
- Our animal model of repetitive blast-induced mTBI is **translationally relevant** and permits us to both model, and in some instances predict, specific aspects of **regional brain dysfunction** in Veterans with blast-induced mTBI
- **Long-term consequences of these brain abnormalities** make long-term follow-up of these Veterans essential.
- There is a need for effective treatments to **ameliorate current symptoms** and **prevent long-term neurodegeneration**.

Collaborators

- **VA MIRECC**
  - Murray Raskind, MD
  - Eric Petrie, MD
  - Kathleen Pagulayan, PhD
  - Cynthia Mayer, DO
  - Kim Hart, PA-C
  - David Hoff, PA-C
  - Robert Turner, PA-C
  - Jane Shofer, MS
  - Steven Millard, PhD
  - James Meabon, PhD
  - Desiree Marshall, MD
- **VA GRECC**
  - David Cook, PhD
  - Charles Wilkinson, PhD
  - Chang-En Yu, PhD
  - William Banks, MD
  - Brian Kraemer, PhD

University of Washington

- Vasily Yarnykh, PhD
- Natalia Kleinhans, PhD
- Todd Richards, PhD
- Tom Montine, MD, PhD
- Jing Zhang, MD, PhD
- Dirk Keene, MD, PhD
- Randall Leveque, PhD
- Pierre Mourad, PhD
- Melissa Reilly

University of Utah

- Satoshi Minoshima, MD, PhD
- Donna Cross, PhD

- **Baker Risk, San Antonio**
  - Ray Bennett, PhD

Supported by the Department of Veterans Affairs

Collaborators

Special thanks to:

- Command Sgt Maj (ret) Thomas Adams
- Command Sgt Maj Robert Prosser
- First Sgt (ret) Creed McCaslin

First Stryker Brigade (Lancers), 25th Infantry Division, Mosul, Iraq, 2004-2005


ADAMS